Consensus Statement

JOURNAL OF HEPATOLOGY

A multisociety consensus statement on a new common definition and diagnostic criteria for PSVD or NCPF

Virginia Hernández-Gea[1,2,3,*], Valerie Paradis[4,5], Maha Guindi[6], Venancio A.F. Alves[7], Amal Aqul[8], Eira Cerda[9], Sarwa Darwish Murad[10], Prasenjit Das[11], Angelo Di Giorgio[12], Luiz A.R. de Freitas[13], Tassos Grammatikopoulos[14,15], Kenichi Harada[16], Nelia Hernandez[17], Samar H. Ibrahim[18,19], Sanjay Kakar[20], Saul Karpen[21], David E. Kleiner[22], Necati Ormeci[23], Xiaolong Qi[1,24], Puja Sakhuja[25], Maria Isabel Schinoni[26], Romil Saxena[27], Alexandre Sayadi[4,5], Akash Shukla[28], Dina G. Tiniakos[29,30], Elizabeth Verna[31], Kerry Wong[32], Laure Elkrief[33], Christine Sempoux[34], Theo Heller[35], Pierre-Emmanuel Rautou[4,5,*]

Abstract

Non-cirrhotic portal hypertension has historically been described using heterogeneous and region-specific terminology, such as idiopathic portal hypertension (IPH), non-cirrhotic portal fibrosis (NCPF), obliterative portal venopathy, and nodular regenerative hyperplasia, leading to substantial variability in diagnosis, reporting, and international research collaboration. Differences in guideline definitions from major societies (AASLD, EASL, and APASL), together with the presence of characteristic histologic lesions in patients without clinically overt portal hypertension, have further complicated disease classification. To address these challenges, a large, multisociety, international initiative was convened to harmonize nomenclature and diagnostic criteria. Representatives from liver, pathology, and pediatric hepatology societies across the Americas, Europe, and Asia participated in a structured consensus process that included specialized working groups and external Delphi validation. The initiative produced a globally harmonized and implementable diagnostic framework. Consensus was reached that the terms porto-sinusoidal vascular disorder (PSVD) and NCPF may be used interchangeably when identical diagnostic criteria are applied, and that they should be written as *PSVD or NCPF*. The diagnosis was defined as fundamentally clinicopathological, requiring integrated assessment. Core principles include the need for a high-quality liver biopsy (≥10 mm), mandatory exclusion of cirrhosis, and systematic exclusion of specific alternative conditions. Importantly, the consensus recognizes that PSVD or NCPF may be diagnosed even without clinical portal hypertension and may coexist with other liver diseases, provided cirrhosis is excluded. Standardized major and minor histologic criteria were developed collaboratively by expert pathologists and externally validated. Features of portal hypertension were harmonized into specific and nonspecific categories applicable to routine clinical practice. An integrated diagnostic scoring system incorporating histology, clinical features, associated conditions, and concommitant etiologies was developed and validated using the Delphi method. This consensus provides the first internationally endorsed, unified framework for the diagnosis of PSVD or NCPF. Its global implementation is expected to reduce diagnostic variability, improve comparability across regions, and facilitate the development of robust, internationally harmonized clinical and translational research cohorts.

© 2026 The Authors. Published by Wolters Kluwer Health, Elsevier B.V., Springer Nature, and Elsevier España S.L.U. on behalf of American Association for the Study of Liver Diseases, European Association for the Study of the Liver, Asian Pacific Association for the study of the Liver and Fundación Clínica Médica Sur, A.C. This is an open access article under the CC BY-NC-ND license (http://creativecommons.org/licenses/by-nc-nd/4.0/).

Introduction

Portal hypertension in the absence of cirrhosis was first described in the late 19th century, with reports dating back to 1880.[1] Since then, a wide array of terms has been used to describe this heterogeneous condition, reflecting either clinical phenotypes (*e.g.*, idiopathic portal hypertension [IPH], non-cirrhotic portal hypertension [NCPH], early-onset familial non-cirrhotic portal hypertension, and non-cirrhotic portal fibrosis) or histopathological features (*e.g.*, obliterative portal venopathy, nodular regenerative hyperplasia [NRH], hepatoportal sclerosis, and incomplete septal fibrosis [ISF]/cirrhosis).

The adoption of specific terminology has historically been driven more by regional practices and cultural context than by shared scientific consensus. In most Asian countries, the terms

* Corresponding author. Addresses: Department of Hepatology, Liver Unit, Hospital Clinic-IDIBAPS, 170 Villarroel, Barcelona 08036, Spain or Department of Hepatology, Service d'Hépatologie, Hôpital Beaujon, Assistance Publique des Hôpitaux de Paris, 100 Boulevard du Général Leclerc, Clichy 92110, France. *E-mail address:* vihernandez@clinic.cat (V. Hernandez-Gea), pierre-emmanuel.rautou@inserm.fr (P.-E. Rautou)

This paper was jointly developed by Hepatology, Journal of Hepatology, Hepatology International, and Annals of Hepatology and jointly published by Wolters Kluwer Health, Inc., Elsevier B.V., Springer Nature, and Elsevier España S.L.U. The articles are identical except for minor stylistic and spelling differences in keeping with each journal's style. Either citation can be used when citing this article.
https://doi.org/10.1016/j.jhep.2026.04.030

non-cirrhotic portal fibrosis (NCPF) and idiopathic portal hypertension (IPH) have been preferred to describe intrahepatic disorders characterized by portal hypertension in the absence of cirrhosis and without an identifiable cause. Although the histological features attributed to porto-sinusoidal vascular disorder (PSVD) are well described within the spectrum of NCPF/IPH,[2] these definitions are not entirely interchangeable and largely reflect differences in historical context, diagnostic frameworks, and regional clinical practice.

Subtle but relevant differences also exist across major clinical practice guidelines, including those from the American Association for the Study of Liver Diseases (AASLD),[3] the European Association for the Study of the Liver (EASL),[4] and the Asian Pacific Association for the Study of the Liver (APASL),[2] particularly with respect to disease definition and diagnostic criteria. While these discrepancies may appear modest, the lack of full harmonization has created practical challenges, complicating efforts to combine international cohorts, to distinguish from shared region-specific disease characteristics, and to advance mechanistic understanding. Furthermore, the recognition that characteristic histological lesions may be present even in the absence of clinically overt portal hypertension[5–7] has underscored the need for a unifying and inclusive definition capable of encompassing the full disease spectrum.

Despite longstanding recognition, this entity remains poorly characterized from a biological and mechanistic standpoint. Research has largely been dominated by descriptive observational cohorts, reflecting the substantial clinical, hemodynamic, and histological heterogeneity observed among patients. A broad range of histopathological patterns and associated systemic conditions has been reported, further complicating disease classification. Although the concept of a "common pathogenic mechanism" is frequently invoked to justify grouping these entities under the PSVD umbrella, this hypothesis has not yet been conclusively demonstrated.[8]

As a consequence, translational research remains limited, pathophysiological insights are still preliminary, and progress toward mechanism-driven therapeutic development has been modest. Clinically, patients are often managed according to cirrhosis-based paradigms, despite important differences in underlying vascular biology and disease mechanisms.

In an effort to standardize nomenclature and facilitate progress, the Vascular Liver Disease Interest Group (VALDIG) and the Baveno Consensus Conference introduced the term porto-sinusoidal vascular disorder (PSVD).[8,9] This umbrella term was proposed based on the assumption of a shared pathogenic process affecting the portal and sinusoidal vascular compartments, ultimately leading to a common clinical phenotype, namely, noncirrhotic portal hypertension. Although this change in terminology stimulated research activity and fostered the development of larger, well-characterized collaborative studies worldwide, global acceptance of the term has remained incomplete. Concerns persist regarding both the conceptual definition and the terminology of PSVD.[2,10–12]

These challenges have been widely recognized across scientific societies, prompting a broad, multistakeholder initiative involving academic experts representing EASL, AASLD, APASL, and the Latin American Association for the Study of the Liver (ALEH), as well as the European Society of Pathology (ESP), the Society of GI and HPB Pathologists of India (SGIHPBPs), the Brazilian Society of Pathology, the Japanese Society of Pathology, the Hans Popper Hepatopathology Society, and pediatric hepatology societies including the North American Society for Pediatric Gastroenterology, Hepatology and Nutrition (NASPGHAN) and the European Society for Paediatric Gastroenterology, Hepatology and Nutrition (ESPGHAN). The primary objective of this initiative was to address existing controversies and to develop an international consensus on nomenclature, definition, and diagnostic criteria for this complex disease entity.

Methods

Nomenclature Group and Delphi panel composition

The consensus process was led by a chair (Virginia Hernandez-Gea) and overseen by a Steering Committee (SC) composed of 2 representatives from each participating society (n = 16). To ensure comprehensive expertise and broad geographic representation, a Scientific Advisory Board (SAB) was established, including additional experts (n = 13) nominated by their respective societies (Table 1). The total group will be referred to thereafter as the Nomenclature Group. The liver pathologists in the Nomenclature Group formed the Nomenclature Pathology Group.

Given that existing definitions rely on both histopathological and clinical criteria, 4 dedicated working groups (WGs) were formed to develop standardized proposals for each component of the definition (Supplemental Table S1).

- WG1: Definition of liver biopsy adequacy and histological lesions required for the diagnosis of this entity
- WG2: Conditions and histological lesions to be excluded from the diagnosis of this entity
- WG3: Clinical conditions associated with this entity
- WG4: Definition of signs of portal hypertension

The outputs of each WG were reviewed by the Nomenclature Group and underwent structured voting. For areas lacking robust scientific evidence, multiple structured questionnaires were used to achieve expert consensus.

To further enhance geographic diversity and external validation, a Delphi panel was convened, comprising an additional 42 experts nominated by the participating societies (up to 5 members per society) (Table 2). Individual teleconferences were organized with each society, involving Delphi panel members, their representatives in the Nomenclature Group, and the chair. During these meetings, the rationale for the diagnostic score and the supporting analyses were presented and discussed. Delphi panel members were subsequently invited to independently evaluate the proposal and vote on their level of agreement with the diagnostic score. Following completion of the Delphi voting process, the SC convened in person in Paris on December 3,

Table 1. Nomenclature Group members.

Chair	Virginia Hernandez-Gea	
Organization	**Steering Committee**	**Scientific Advisory Board**
AASLD	Theo Heller, Samar Ibrahim	Elizabeth Verna, Saul Karpen, Sanjay Kakar
EASL	Pierre Emmanuel Rautou, Laure Elkrief	Sarwa Darwish Murad
ALEH	Eira Cerda, Marisa Schinoni	Nelia Hernandez
APASL	Necati Ormeci, Xiaolong Qi	Akash Shukla
ESP	Valerie Paradis, Christine Sempoux	Dina G. Tiniakos
Hans Popper Society	David E. Kleiner, Maha Guindi	Romil Saxena
Society of GI & HPB Pathology of India	Puja Sakhuja	Prasenjit Das
Japanese Society of Pathology	Kenichi Harada	—
Brazilian Society of Pathology	Luiz A.R. de Freitas, Venancio A.F. Alves	—
ESPGHAN	—	Tassos Grammatikopoulos, Angelo Di Giorgio
NASPGHAN	—	Kerry Wong, Amal Aqul

Representation of the overall chair and members appointed by participating scientific societies.
Abbreviations: AASLD, American Association for the Study of Liver Diseases; ALEH, Latin American Association for the Study of the Liver; APASL, Asian Pacific Association for the Study of the Liver, EASL, European Association for the Study of the Liver; ESP, European Society of Pathology; ESPGHAN, European Society for Paediatric Gastroenterology, Hepatology and Nutrition; NASPGHAN, North American Society for Pediatric Gastroenterology, Hepatology and Nutrition.

2025, for a final consensus meeting to review, ratify, and finalize all agreed-upon recommendations.

Analysis

The consensus methodology integrated evidence from the published literature, input from the European Cooperation in Science and Technology (COST) Action on Vascular Liver Diseases (EURO-VALDI-NET),[13] and the identification of ongoing research projects and unpublished data to ensure that all relevant and emerging information was considered.

For each survey item, response frequencies were calculated across all answer categories. Respondents selecting "prefer not to vote" were excluded from the denominator, and agreement proportions were calculated based on the remaining valid responses. Answers recorded on the 4-point Likert scale were subsequently recoded into a dichotomous format (agree + somewhat agree *vs*. somewhat disagree + disagree) to determine whether consensus met the predefined threshold.

Consensus was defined a priori as an agreement level of ≥75% among members of the Nomenclature Group.

Based on the combined outputs of the working groups and the consensus voting process, the Nomenclature Group developed a novel diagnostic scoring system for this entity. To quantify the relative diagnostic contribution of clinical, radiological, and histological domains, 36 hypothetical scenarios were constructed using all possible combinations of portal hypertension categories, histological patterns, associated conditions, and the presence or absence of cirrhosis. Members of the Nomenclature Group voted on whether each scenario was compatible with PSVD/NCPF. Scenarios achieving ≥75% agreement among participants were classified as PSVD/NCPF, those with <50% agreement as non-PSVD/NCPF, and intermediate cases as possible PSVD/NCPF.

Analysis of the voting results identified the domains that most strongly influenced diagnostic confidence, which were subsequently translated into weighted points. Major histological criteria emerged as the strongest predictors of PSVD/NCPF, followed by unequivocal signs of portal hypertension, whereas the presence of cirrhosis reduced diagnostic certainty. In a final step, each individual component was assigned a numerical value and integrated into a composite score. This score reproduced 100% of expert agreement across all voted scenarios and informed the development of a quantitative diagnostic model integrating expert consensus across domains. According to the proposed score, all 36 hypothetical scenarios fully reflected the experts' votes and were therefore retained.

Results

Toward a uniform terminology

The Nomenclature Group reviewed all terminology currently used in the literature and carefully evaluated the potential advantages and limitations of introducing a new term. At the same time, the practical challenges associated with changing established terminology were acknowledged, particularly in regions where the disease is highly prevalent, such as parts of Asia, and where implementation of new terminology in routine clinical practice may be constrained by limited resources.

During its meeting on December 3, 2025, the SC therefore adopted a pragmatic approach allowing the 2 most widely used terms to coexist, provided that identical diagnostic

Table 2. Delphi panel members.

Society	Name
AASLD	Juan G. Abraldes
	Scott Biggins
	Guadalupe Garcia-Tsao
	Valérie A. McLin
	Don Rockey
ALEH	Raymundo Paraná
	Wagner Ramírez-Quesada
	Ezequiel Ridruejo
	Antonio Velarde
APASL	Diana Alcantara Payawal
	A. Kadir Dökmeci
	Lubna Kamani
	Shiv Sarin
	Hakan Şentürk
Argentinian Society of Pathology	Marcelo Amante
Chilean Society of Pathology	Marcela Javiera Torres
EASL	Louise China
	Andrea de Gottardi
	Juan Carlos García Pagán
	Aurélie Plessier
	Marco Senzolo
ESP	Michail Doukas
	Alessandro Gambella
	Anne Hoorens
	Prodromos Hytiroglou
	Funda Yilmaz
ESPGHAN	Oanez Ackermann
	Maria Mercadal Hally
	Hubert van de Doef
Hans Popper Society	Daniela Allende
	Cynthia Behling Sharp
	Isabel Fiel
	Dhanpat Jain
	Rish Pa
Japanese Society of Pathology	Mina Komuta
NASPGHAN	Lee Bass
	Susan Gilmour
	Mercedez Martinez
	Jean Moleston
	Ben Shneider
SGIHPBPs	Chhagan Bihari
	Mukul Vij

Representation of the members appointed by participating scientific societies.
Abbreviations: AASLD, American Association for the Study of Liver Diseases; ALEH, Latin American Association for the Study of the Liver; APASL, Asian Pacific Association for the Study of the Liver, EASL, European Association for the Study of the Liver; ESP, European Society of Pathology; ESPGHAN, European Society for Paediatric Gastroenterology, Hepatology and Nutrition; NASPGHAN, North American Society for Pediatric Gastroenterology, Hepatology and Nutrition, SGIHPBPs, Society of GI and HPB Pathologists of India.

criteria, as defined herein, are applied. It was agreed that the terms "PSVD" and "NCPF" would be used interchangeably. For simplicity, the entity is referred to as "PSVD/NCPF" throughout the present manuscript.

Finally, the SC voted on whether PSVD should be defined as a porto-sinusoidal vascular *disease*, as originally proposed by VALDIG,[8] reflecting the concept of a shared clinical entity despite histological heterogeneity and diverse associated conditions, or as a porto-sinusoidal vascular *disorder*, as later adopted by the Baveno consensus[9] to emphasize heterogeneity and provide a broader umbrella term. In the absence of definitive scientific evidence supporting either conceptual framework, the Nomenclature Group proceeded with a formal vote. The term *disorder* was selected (74% agreement), based on the rationale that it more appropriately encompasses multiple subgroups that may ultimately be delineated as distinct entities as mechanistic understanding evolves.

Fundamental concepts

The Nomenclature Group reached consensus that a high-quality liver biopsy is mandatory for diagnosis, that cirrhosis must be excluded, and that the entity can be diagnosed in the absence of signs of portal hypertension.

Statement 1

A liver biopsy is mandatory for the diagnosis of PSVD or NCPF. (Agreement 95%)

Statement 2

Exclusion of cirrhosis using a good-quality liver biopsy is necessary. (Agreement 100%)

Statement 3

PSVD or NCPF can be diagnosed in the absence of signs of portal hypertension. (Agreement 92%)

Following agreement on these fundamental principles, participants were assigned to predefined WGs, which subsequently evaluated all components required for the definition

and worked toward developing a unified, consensus-based definition of the entity.

Definition of liver biopsy adequacy

Previous definitions of PSVD[8] and NCPF[2] stated that diagnosis requires an adequately sized liver needle biopsy, ideally ≥20 mm in length, with at least 10 portal tracts, with minimal fragmentation, or overall adequacy for interpretation by an expert pathologist. However, these recommendations were largely based on expert consensus rather than on evidence derived from studies specifically designed to address biopsy quality requirements. During the consensus process, WG1 considered newly available evidence defining minimum biopsy quality standards to exclude cirrhosis.[14] These data demonstrate that a biopsy length of at least 15 mm, with at least 1 fragment measuring ≥10 mm, is sufficient to reliably exclude cirrhosis, with no additional diagnostic benefit from longer samples. After reviewing these findings, the Nomenclature Group accepted this evidence-based definition as the minimum standard for an adequate liver biopsy to exclude cirrhosis in the context of suspected PSVD/NCPF. At present, however, no robust data are available to define biopsy characteristics required to optimally identify histological lesions of PSVD/NCPF.

Statement 4
A biopsy of 15 mm length with at least 1 fragment ≥10 mm is sufficient to reliably exclude cirrhosis in case of suspicion of PSVD or NCPF. (Agreement 100%)

Harmonization of conditions to be excluded from the diagnosis

The exclusion of conditions from the definition of PSVD/NCPF is an evolving field, as emerging data are continuously reshaping disease boundaries.

WG2 systematically reviewed all conditions that had been established as exclusion criteria in previous guidelines.[3,4,7,8] In the absence of newly published or emerging data, these conditions were retained as exclusion criteria. Based on novel data, the following conditions were re-evaluated in depth and eventually removed as exclusion criteria: portal cavernoma, sinusoidal obstruction syndrome (SOS), and schistosomiasis.

Although portal vein thrombosis (PVT) in patients who otherwise fulfilled diagnostic criteria for PSVD/NCPF was permitted in previous definitions, the presence of cavernous transformation of the portal vein was considered an exclusion criterion.[8] However, new unpublished data from a European cohort with longitudinal imaging demonstrate that patients with PSVD/NCPF may develop portal cavernoma (*i.e.*, presence of multiple dilated peribiliary and/or gallbladder wall veins [>2 mm] irrespective of the patency of the main portal vein) during the disease course.[15] In all the cases described, the cavernoma was intrahepatic. After reviewing these data, the panel agreed that the presence of an intrahepatic cavernoma does not exclude a diagnosis of PSVD/NCPF.

The diagnosis of SOS following hematopoietic stem cell transplantation should not be considered synonymous with PSVD/NCPF. Nevertheless, recent longitudinal data demonstrated that survivors of SOS may develop portal hypertension during long-term follow-up. In a small European cohort, repeat liver biopsies performed more than 6 months after SOS diagnosis revealed histological features consistent with PSVD/NCPF, suggesting that SOS may evolve into a PSVD-like histological pattern.[16] Based on these findings, it was decided that a history of SOS more than 6 months prior does not preclude a diagnosis of PSVD/NCPF.

Finally, schistosomiasis was re-assessed based on extensive clinicopathological experience from Latin American experts and a review of the available literature. The panel agreed that in endemic areas, and in the absence of hepatosplenic schistosomiasis, a positive serology or the incidental finding of a limited number of parasite eggs in the liver may coexist with PSVD/NCPF and should not be considered exclusion criteria (Table 3).

Statement 5
The conditions listed in Table 3 should be excluded to establish the diagnosis of PSVD or NCPF. (Agreement 100%)

Harmonization of conditions associated with PSVD or NCPF

PSVD/NCPF has been associated with a wide range of clinical conditions and risk factors, although a definitive causal relationship has not been established for most of them. Nevertheless, the presence of these associated conditions, both in

Table 3. Exclusion criteria.

1	Abernethy syndrome
2	Budd-Chiari syndrome or hepatic venous outflow obstruction
3	Cardiac failure or Fontan-associated liver disease
4	Cholestatic liver diseases
5	Congenital hepatic fibrosis
6	Gaucher disease
7	Hepatic amyloidosis
8	Hereditary hemorrhagic telangiectasia
9	Hypervitaminosis A
10	Intrahepatic arteriovenous shunts
11	Liver infiltration by tumor cells
12	Peliosis hepatis
13	Schistosomiasis*
14	SOS in the last 6 months**

*In endemic areas and in the absence of hepatosplenic schistosomiasis, apositive serology or the incidental finding of a few parasite eggs in the liver can occur in PSVD and are not exclusion criteria.
**Six months or more after bone marrow transplantation, PSVD can develop in patients previously diagnosed with SOS (sinusoidal obstruction syndrome).
Abbreviation: PSVD, porto-sinusoidal vascular disorder.

Table 4. Associated conditions.

Category	Condition/Exposure
Drug Exposure	Azathioprine
	6-Thioguanine exposure
	Methotrexate exposure
	Oxaliplatin
	Didanosine
	Stavudine
	Arsenic exposure
	Vinyl chloride
	Trastuzumab-Emtansine
Genetic Diseases	Adams-Oliver Syndrome (*NOTCH1, ARHGAP31*, etc.)
	Telomere Biology Disorders (*TERT, TERC, DKC1*, etc.)
	Retinal Vasculopathy with Cerebral Leukoencephalopathy and Systemic manifestations (*TREX1*)
	Chronic Granulomatous Disease (*CYBB, NCF1, NCF2*, etc.)
	X-Linked Agammaglobulinemia (Bruton's) (*BTK*)
	Activated PI3K Delta Syndrome (*PIK3CD, PIK3R1*)
	Hyper IgM Syndrome (*CD40L, AICDA, UNG*, etc.)
	Cystic Fibrosis (*CFTR*)
	Cystinosis (*CTNS*)
	William-Beuren Syndrome (ELN)
	Turner's Syndrome
	Pierpont Syndrome (*TBL1XR1*)
	Developmental Disorders (*NOTCH1, CTC1*)
	CNN3 gene mutation
	DGUOK gene mutation
	Familial Obliterative Portal Venopathy (*FOPV*)
	GIMAP5 gene mutation
	FCHSD1 gene mutation
	TRMT5 gene mutation
	HRG gene mutation
	TACI gene mutation
	Deficiency of Adenosine Deaminase 2 (*DADA2*)
Hematologic and Prothrombic Diseases	Anti-phospholipid antibodies and anti-phospholipid antibody syndrome
	Protein C deficiency
	Protein S deficiency
	Antithrombin deficiency
	Factor V Leiden mutation
	Prothrombin gene mutation
	ADAMTS13 deficiency
	Hodgkin's lymphoma
	Multiple myeloma
	Marginal B cell lymphoma
	Monoclonal gammopathy of uncertain significance
	Chronic lymphoid leukemia
	Paroxysmal hemoglobinuria
	Aplastic anemia
	Idiopathic thrombocytopenia purpura
	Myeloproliferative neoplasms
Immune/Inflammatory Diseases	Common variable immunodeficiency syndrome
	Castleman disease
	Systemic lupus erythematosus
	Progressive systemic sclerosis
	Rheumatoid arthritis / Felty's syndrome
	Still's disease
	Vasculitis
	Sjögren syndrome
	Mixed connective tissue disease
	Inflammatory bowel disease
	Celiac disease
	POEMS syndrome
	Autoimmune nephropathy
	Behçet disease
	Sarcoidosis without biliary/centrilobular involvement
	Dermatomyositis
Transplantation	Solid organ transplantation
Infection	Recurrent/chronic low-grade abdominal infections
	Human Immunodeficiency Virus

Note: List of conditions agreed among experts based on available literature and personal experience to be associated with PSVD/NCPF.
Abbreviations: NCPF, noncirrhotic portal fibrosis; PSVD, porto-sinusoidal vascular disorder.

adults and in children, may provide important diagnostic support, particularly in cases with uncertain clinical or histological findings.[17–19]

The frequency and relative relevance of associated conditions differ by geographic region. Nevertheless, across all regions, associated conditions are observed in a majority of patients, with reported prevalence of ~70% in Latin American cohorts,[20] 60% in European series,[21] and 40% in China.[22] Up to one-third of the patients exhibit multiple concomitant conditions, while approximately one-third have no identifiable associated condition.[21]

To address this heterogeneity, the Nomenclature Group conducted a comprehensive literature review to compile all previously reported conditions associated with PSVD/NCPF. Panel members then voted on whether each condition was considered relevant, based on their clinical experience. Given the substantial regional variability in presentation and differences in exposure patterns, the Nomenclature Group agreed to apply a lower consensus threshold for this specific item. Conditions receiving agreement from 50% or more of participants were retained, reflecting relevance across multiple regions rather than universal applicability. It should be acknowledged that the spectrum of associated conditions is likely to evolve as new data emerge. Accordingly, this list (Table 4) should be viewed as dynamic and subject to future revision as additional mechanistic, (epi)genetic, and epidemiological evidence becomes available.

Impact of concomitant causes of cirrhosis

Some patients with PSVD/NCPF may also have concomitant liver conditions known to cause cirrhosis, which substantially complicates the diagnostic process. On one hand, the presence of a recognized cause of chronic liver disease reduces the likelihood of considering PSVD/NCPF as a diagnosis, and this has been associated with documented cases of misclassification.[23] Indeed, PSVD/NCPF has been identified retrospectively on explanted livers from patients transplanted with a preoperative clinicoradiological diagnosis of cirrhosis,[24] highlighting the risk of diagnostic oversight. On the other hand, when another cause of chronic liver disease is present, the pretest probability of having PSVD/NCPF decreases, given the substantially higher likelihood of development of cirrhosis in these conditions. Nevertheless, PSVD/NCPF may coexist with established causes of developing cirrhosis, highlighting the importance of assessing whether the vascular component is the main driver of portal hypertension and of the clinical phenotype rather than the other etiology of chronic liver disease.

Consensus pathway toward definition of histological lesions associated with the diagnosis of PSVD or NCPF

The Nomenclature Group identified an ongoing initiative within the EURO-VALDI-NET (https://eurovaldinet.eu/) and agreed to coordinate efforts, aligning with the objectives of WG2 of the COST Action: *Extensive histological characterization of PSVD*. This initiative was led by 9 European liver pathologists.[15] The EURO-VALDI-NET WG2 and the Nomenclature Pathology Group worked jointly to identify and define the histological lesions characterizing PSVD/NCPF. Preliminary results generated by EURO-VALDI-NET WG2 were presented to, critically reviewed by, and validated within the Nomenclature Group.

Briefly, the EURO-VALDI-NET WG2 initially selected reference material comprising 50 adequate virtual liver biopsies derived from 10 reduced liver grafts. A detailed morphometric analysis of normal liver vascular structures was performed (step #1). Assessed parameters included the number of portal tracts, hepatic arterioles, bile ducts, portal venules, major and minor axes, and endothelial surface of vascular structures (portal venules and arterioles). These measurements were used to establish reference values for normal portal tract structure and to define quantitative thresholds for diagnostic histological lesions.

Subsequently, 58 liver biopsies (42 from patients with PSVD/NCPF and 16 liver biopsies from living donors and systematic post-liver transplant biopsies) were analyzed to define histological features associ-ated with PSVD/NCPF and their reproducibility among the 9 European pathologists (step #2). The definition of each elementary histological lesion was established based on a literature review and the results of step #1 (*i.e.*, analysis of normal liver), using Hematoxylin & Eosin, Picro-Sirius Hematoxylin, and reticulin stains. Lesions assessed included abnormal distribution of vascular structures (central veins and portal tracts), NRH, sinusoidal dilatation, sinusoidal fibrosis, portal fibrosis, bridging fibrosis, ISF, central vein lesions, portal venule stenosis, muscularized portal venules, herniated or dilated portal venules, hypervascularized or hyperarterialized portal tracts, abnormal periportal vessels, portal inflammation, interface hepatitis, and lobular inflammation.

Subsequently, an illustrated atlas containing representative images and standardized definitions of each lesion was developed and shared with the Nomenclature Pathology Group. Following review, discussion, and refinement, consensus definitions were agreed upon. This atlas was made publicly available on the VALDIG website.[25]

Importantly, the lesions associated with PSVD/NCPF are not pathognomonic and may also occur in other liver diseases.[12] In light of their limited diagnostic specificity, the Nomenclature Group abandoned the term “specific lesions” and instead adopted a framework distinguishing *major* and *minor* histological criteria.

Using these standardized definitions, a total of 218 liver biopsies were subsequently evaluated (step #3). This cohort included 41 normal liver samples from living donors, 89 controls with chronic liver disease (alcohol-associated liver disease, metabolic dysfunction–associated steatotic liver disease [MASLD], viral hepatitis, autoimmune hepatitis), and 88 cases of PSVD/NCPF with specific signs of portal hypertension. Biliary diseases were not included, as they constitute an exclusion criterion for the definition of PSVD/NCPF. Initial scoring was performed by the 9 liver pathologists from the COST Action WG2, who assessed both the presence and semiquantitative extent of each lesion. An elementary lesion was considered present in a biopsy when more than 50% of the pathologists reported the feature. Statistical analyses were then conducted on all 218 liver biopsies to establish major or minor histological criteria for PSVD/NCPF. Thresholds for identifying major and minor criteria were defined a priori. Major criteria were defined as lesions with a specificity >0.95 and a sensitivity >0.10 for PSVD/NCPF. Minor criteria were defined as lesions with a

specificity between 0.80 and 0.94 and a sensitivity >0.10 in biopsies lacking major criteria.

Based on this consensus process, **major histological criteria** were defined as the presence of any of the following: NRH, muscularized portal venules, or portal venule stenosis involving 50% or more of portal tracts. **Minor histological criteria** included regenerative changes in the absence of NRH, abnormal distribution of vascular structures, or portal venule stenosis involving 25%–49% of portal tracts. Importantly, the concomitant presence of all 3 minor criteria demonstrated a discriminative capacity comparable to that of a single major criterion (Fig. 1). These criteria can be applied to diagnose PSVD/NCPF only once the exclusion criteria in Table 3 have been ruled out.

Nine international liver pathologists representing all geographical regions involved in the nomenclature process reviewed the 218 biopsies and validated the selected lesions. All original data supporting these definitions are reported in a separate publication.[15]

Although additional histological abnormalities, such as sinusoidal dilatation or sinusoidal fibrosis, may be observed in PSVD/NCPF, these findings were redundant with the defined major and minor criteria and did not independently enhance diagnostic discrimination.

The final set of histological criteria was formally voted on and approved by the Nomenclature Group.

Statement 6
Major histological criteria for PSVD or NCPF include nodular regenerative hyperplasia (NRH), muscularized portal venules, or portal venule stenosis involving 50% or more of portal tracts. (Agreement 100%)

Statement 7
Minor histological criteria for PSVD or NCPF include regenerative changes in the absence of NRH, abnormal distribution of vascular structures, or portal venule stenosis involving 25%–49% of portal tracts. (Agreement 100%)

Statement 8
Concurrent presence of all 3 minor criteria is considered a major histological criterion. (Agreement 100%)

Harmonized definition of signs of portal hypertension

PSVD or NCPF can be diagnosed in the absence of signs of portal hypertension; this form represents a variable proportion of PSVD/NCPF cases.[5,7,26,27] However, evidence in this setting is limited, and prospective longitudinal studies are required to define disease course and progression. In current practice, PSVD/NCPF is most often identified in patients presenting with signs of portal hypertension.

Given the predominant presinusoidal component of portal hypertension in PSVD, hepatic venous pressure gradient (HVPG) measurements may underestimate portal pressure, as this technique does not capture the presinusoidal contribution. Nevertheless, an HVPG value equal to or more than 10 mmHg remains unequivocal evidence of portal hypertension. Measurement of the porto-caval gradient via percutaneous puncture without general anesthesia is considered the most reliable method for assessing portal pressure, although not widely available; a porto-caval gradient equal to or more than 10 mmHg likewise provides unequivocal evidence of portal hypertension, even when HVPG values are below this threshold. Porto-caval gradient assessment using endohepatology approaches, such as endoscopic ultrasound-guided techniques, can probably be useful in this setting, although validated cutoff values for these methods remain to be established. Despite these considerations and the value of hemodynamic assessment in expert centers, these techniques are not routinely available. Therefore, the group reviewed the available literature and reached consensus on all potential signs of portal hypertension to identify those that can be considered definitive in routine clinical practice.

The Nomenclature Group agreed that gastro-intestinal bleeding due to varices, the presence of medium or large esophageal varices, gastric varices, and spontaneous porto-systemic shunts represent **specific signs of portal hypertension**. In addition, a spleen stiffness measurement >40 kPa,

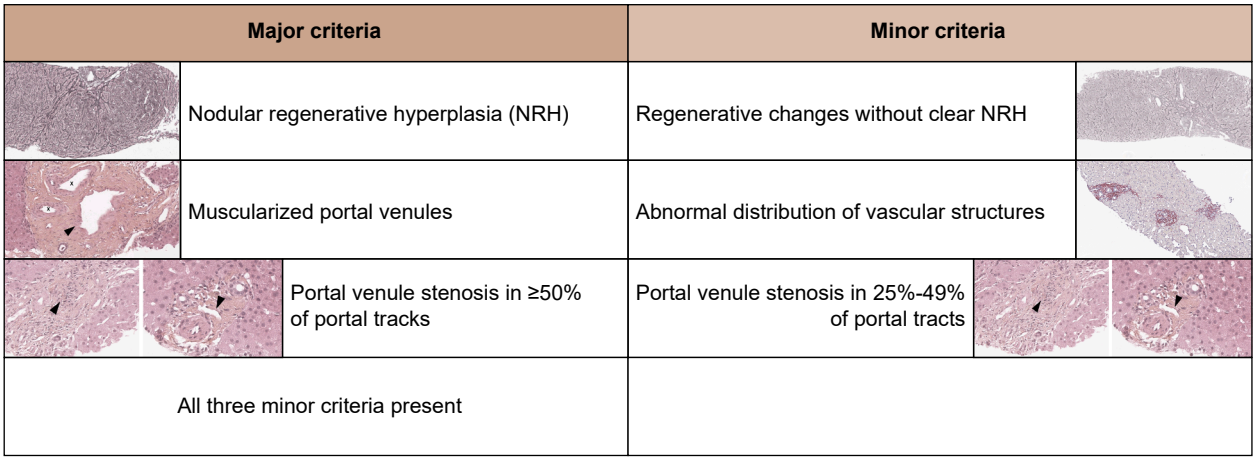

Fig. 1. Histological criteria defining PSVD or NCPF. Abbreviations: NCPF, noncirrhotic portal fibrosis; NRH, nodular regenerative hyperplasia; PSVD, porto-sinusoidal vascular disorder.

Table 5. Specific and nonspecific signs of portal hypertension.

Specific signs of portal hypertension*:	Nonspecific signs of portal hypertension:
Gastrointestinal bleeding dues to varices	Clinical ascites
Medium/large esophageal varices	Small varices
Gastric varices	Low platelet count (< 150 G/L)
Portosystemic shunt	Splenomegaly
Spleen stiffness > 40 kPa in the absence of myeloproliferative neoplasia	

*Hepatic venous pressure gradient (HVPG) or direct measurement of portocaval pressure gradient (PCG) ≥ 10 mmHg are unequivocal signs of portal hypertension and should be considered as specific signs.

in the absence of myeloproliferative neoplasms, was considered a specific marker, based on recently published data[28] and its inclusion in updated APASL guidelines.[2] Clinical ascites, small esophageal varices, thrombocytopenia with platelet counts below 150 G/L, and splenomegaly were considered **non-specific signs of portal hypertension** (Table 5).

Creation of a diagnostic score

The Nomenclature Group identified 4 key clinical domains as central to the diagnosis of PSVD/NCPF in routine clinical practice, provided that exclusion criteria are absent and cirrhosis has been ruled out on an adequate liver biopsy. These domains included the presence of portal hypertension, histological features, associated conditions, and concomitant causes of cirrhosis. Rather than adhering strictly to previous definitions, the Nomenclature Group concluded, after multiple dedicated meetings and structured discussions, that these 4 variables best define the diagnostic and clinical suspicion framework of the disease.

To evaluate the relative importance of each component, 36 hypothetical clinical scenarios were generated (Supplemental Fig. S1), incorporating all possible combinations of these variables (see methods section). Portal hypertension was categorized into 3 groups: absence of signs of portal hypertension, presence of nonspecific, or specific signs of portal hypertension. Histological findings were classified as normal liver histology, only minor histological criteria, or major histological criteria. Associated conditions and concomitant causes of cirrhosis were each considered as either present or absent.

Nomenclature Group members were asked to vote on whether each scenario was compatible with the diagnosis of PSVD/NCPF. This structured voting approach allowed estimation of the relative diagnostic contribution of each domain. Scenarios with ≥75% agreement were classified as definite diagnosis of PSVD/NCPF, those with <50% agreement as no PSVD/NCPF, and those with intermediate agreement as possible PSVD/NCPF. Analysis of the voting results showed that the presence of major histological criteria was the strongest factor supporting the diagnosis of PSVD/NCPF, followed by the presence of specific signs of portal hypertension. In contrast, the coexistence of a cause of cirrhosis had a negative impact on diagnostic confidence and contributed to uncertainty in several clinical scenarios. Based on these expert assessments, a diagnostic score was developed to quantitatively reflect consensus opinion across participating societies. The diagnostic score integrates histological lesions, signs of portal hypertension, and concomitant conditions, following exclusion of cirrhosis on an adequate liver biopsy and the absence of established exclusion criteria (Fig. 2).

Clinical features related to portal hypertension are weighted as follows: absence of portal hypertension (0 points), only non-

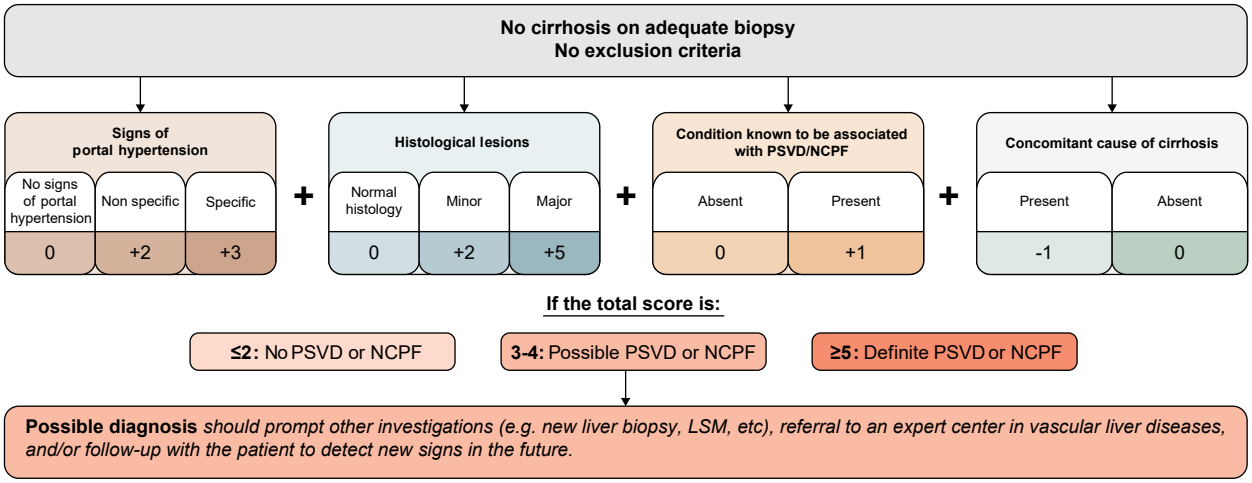

Fig. 2. Diagnostic score PSVD or NCPF. For each category, the score is based on the highest applicable criterion. If both minor and major criteria are present, only the major criterion will be considered. If multiple criteria within the same category are met, the score is not cumulative, only one criterion will be counted. LSM, liver stiffness measurement; NCPF, noncirrhotic portal fibrosis; PSVD, porto-sinusoidal vascular disorder.

specific signs of portal hypertension (2 points), and 1 or more specific signs of portal hypertension (3 points). Histological findings are graded as normal liver (0 points), up to 2 minor criteria (2 points), and 1 or more major criteria or 3 minor criteria (5 points). Concomitant conditions previously reported to be associated with PSVD/NCPF contribute +1 point, whereas conditions known to cause cirrhosis result in a −1 point adjustment. Based on the cumulative score, the probability of PSVD/NCPF is categorized as follows: ≤2 points, PSVD/NCPF cannot be diagnosed based on existing evidence; 3–4 points, possible PSVD/NCPF, warranting follow-up and/or referral to an expert center; and ≥5 points, PSVD/NCPF confirmed. Notably, the concomitant presence of all 3 minor histological criteria is considered equivalent to 1 major criterion. The presence of more than 1 major histological lesion does not increase the score beyond 5 points, and the combination of major and minor criteria does not result in additional points. The same applies to multiple signs of portal hypertension. Furthermore, during the process, it was acknowledged that metabolic syndrome without histological evidence of metabolic dysfunction–associated steatotic liver disease (MASLD) should not be considered a cause of cirrhosis in the diagnostic score, and thus not lead to "−1."

The Nomenclature Group acknowledges that several histological lesions not included in the scoring system may still provide supportive diagnostic information. Similarly, additional clinical and imaging features, such as low liver stiffness measurement combined with high spleen stiffness measurement, periportal hyperintensity on magnetic resonance imaging, or a nodular liver surface with a normal or enlarged segment IV, may further strengthen diagnostic suspicion but do not provide additional points.

Given that this approach represented a novel, consensus-based diagnostic framework, external validation was sought through an independent Delphi panel. The score was subsequently validated by this Delphi panel with 87% agreement (Fig. 3). Hence, the Nomenclature Group now proposes the use of this standardized and objective tool for the diagnosis of PSVD/NCPF moving forward.

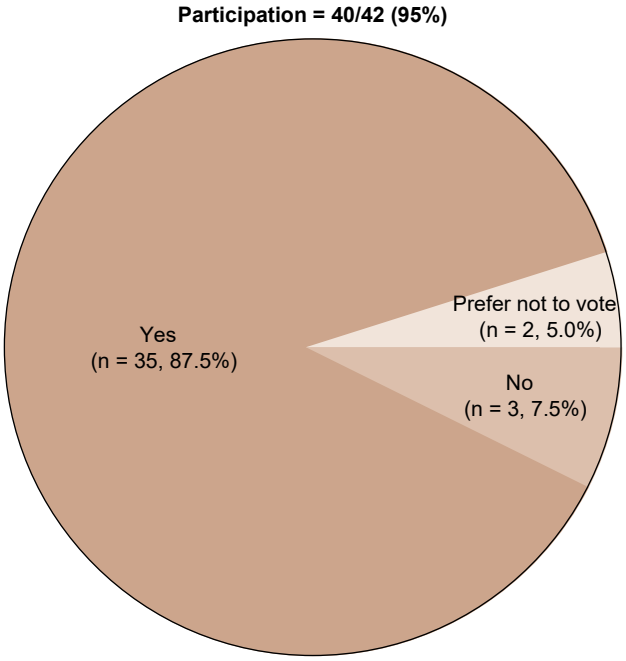

Fig. 3. Validation of the diagnostic score by Delphi members.

Discussion

Establishing a revised definition of this entity has represented a major conceptual and practical challenge since its first descriptions in the late 19th century. Over time, the disorder has been referred to by multiple names and has been accompanied by divergent definitions, which have hindered progress in the field by limiting the ability to merge cross-continental cohorts and combine expertise. This fragmentation has hampered a comprehensive understanding of the disease, including its heterogeneity and natural course. These challenges reflect not only the biological diversity of the entity but also the need to reconcile perspectives from a broad range of stakeholders, including adult and pediatric hepatologists as well as pathologists. The revised definition presented here addresses these limitations by improving scientific accuracy and providing a framework that enhances disease awareness, dissemination, training, education, and patient engagement worldwide.

The present work describes a robust and transparent consensus process that systematically addressed all components required for diagnosis at both clinical and pathological levels. Using an iterative, feedback-driven methodology, consensus was achieved across all key elements of the definition. Approval by a majority of participants (>75%) strengthens the legitimacy of the outcomes and reflects the ethical importance of inclusivity and consideration of diverse expert perspectives.

This proposed definition represents a substantial advance, building on previous terminology efforts, as it is widely endorsed and supported by newly generated scientific data. Importantly, for the first time, the Nomenclature Group developed a pragmatic diagnostic score designed to support clinical decision-making. This score not only facilitates confident diagnosis but also introduces a category of "possible," which had not been formally acknowledged in previous definitions. This intermediate category is expected to improve understanding of the evolution and natural history of the disorder, reduce diagnostic uncertainty, and limit over-diagnosis. It also provides a framework for longitudinal follow-up of these patients, allowing future refinement of diagnostic criteria as additional evidence becomes available. Notably, the diagnostic score was externally validated by a large group of experts nominated by international and national scientific societies, again achieving more than 75% agreement, further supporting its robustness and acceptability. The refined criteria are therefore expected to facilitate interdisciplinary integration and reduce ambiguity in both clinical practice and trial design.

Reaching harmonization of the histological criteria for PSVD/NCPF represented one of the major advances of this process, supported by the generation of new, original data. Previous definitions relied on expert opinion and descriptive reports of selected histological lesions not always named the same way. In contrast, this initiative adopted a data-driven approach in which pathologists first established a rigorous definition of normal portal tracts structure and subsequently identified PSVD/NCPF-associated lesions based on

standardized, consensus-driven criteria and detailed definitions with a unified terminology. An international group of liver pathologists from COST Action EURO-VALDI-NET contributed tremendously to this effort, and lesions demonstrating the highest reliability and diagnostic performance were selected for inclusion in the definition. Nevertheless, the Nomenclature Group acknowledges several limitations. The biopsy cohort used for lesion identification was derived exclusively from European centers and included only patients with specific signs of portal hypertension, although samples were independently evaluated by pathologists from multiple geographic regions. In addition, pediatric liver biopsies were not included in the analyzed data set. Extending this histological framework to patients without portal hypertension and to pediatric populations, therefore, represents an important next step to ensure that the proposed criteria are universally applicable across stages and age groups.

Other limitations of the consensus process should be acknowledged. Although new scientific data supported several key modifications, other aspects necessarily relied on expert consensus in the absence of conclusive evidence. In particular, the diagnostic score was derived from expert opinion rather than prospective validation, which should be addressed in future studies. Furthermore, its direct application to pediatric patients requires caution, as age-specific thresholds for clinical, laboratory, and elastographic parameters are not yet defined. Nonetheless, we consider this an essential first step toward harmonization. The responsibility now lies with the scientific community to generate the data required to validate, refine, or modify this score over time. By continuously refining it, the approach is expected to become more clinically relevant and more widely and sustainably adopted.

The decision to validate and endorse the 2 most widely used terms for the entity (porto-sinusoidal vascular disorder [PSVD] and non-cirrhotic portal fibrosis [NCPF]) as interchangeable under a unified definition further strengthens this initiative. This pragmatic approach promotes international collaboration, acknowledges regional practices, and fosters mutual understanding and respect among the worldwide community.

In conclusion, this consensus provides a strong and credible foundation for advancing the field, based on solid scientific data and broad international expert agreement. The adoption of the revised definition is expected to increase awareness of PSVD/NCPF, improve its diagnostic consistency, and enhance understanding of the underlying pathophysiology and natural history. By providing a clearer and more inclusive framework for related conditions, this initiative has the potential to accelerate biomarker discovery and therapeutic development, ultimately improving outcomes worldwide for people with the disorder.

Affiliations

[1]*Liver disease and the vascular system group (LiVas). Barcelona Hepatic Hemodynamic Laboratory, Liver Unit, Hospital Clínic, Clínic Barcelona, FRCB-IDIBAPS (Fundació de Recerca Clínic Barcelona-Institut d'Investigacions Biomèdiques August Pi i Sunyer), Barcelona, Spain;* [2]*ERN RARE-LIVER (Health Care Provider of the European Reference Network on Rare Liver Disorders), CSUR (Centro de referencia del Sistema Nacional de Salud en Enfermedad Hepática Vascular Compleja en adultos), Spain;* [3]*CIBEREHD (Centro de Investigación Biomédica en Red Enfermedades Hepáticas y Digestivas), AGAUR SGR202101115, Medicine Department, Faculty of Medicine, and Health Science, Universitat de Barcelona, Barcelona, Spain;* [4]*Centre de recherche sur l'inflammation, Université Paris-Cité, Inserm, UMR 1149, Paris, France;* [5]*AP-HP, Hôpital Beaujon, Service d'Hépatologie, DMU DIGEST, Centre de Référence des Maladies Vasculaires du Foie, FILFOIE, ERN RARE-LIVER, Clichy, France;* [6]*Department of Pathology and Laboratory Medicine, Cedars-Sinai Medical Center, Los Angeles, California, USA;* [7]*Department of Pathology, University of São Paulo School of Medicine, CICAP, Pathology, Hospital Alemao Oswaldo Cruz, São Paulo, SP, Brazil;* [8]*Department of Pediatrics, UT Southwestern Medical Center in Dallas/Children's Health, Dallas, Texas, USA;* [9]*Department of Gastroenterology, Central Military Hospital, Mexico City, Mexico;* [10]*Department of Gastroenterology and Hepatology, Erasmus MC University Medical Center, ERN RARE-LIVER Affiliated Center for Rare Vascular Disorders, Rotterdam, The Netherlands;* [11]*Department of Pathology, All India Institute of Medical Sciences, New Delhi, India;* [12]*Pediatric Liver Service, Hospital Santa Maria Misericordia, University of Udine, Urdine, Italy;* [13]*Department of Pathology, Faculty of Medicine of Bahia, Federal University of Bahia, Brazil, Gonçalo Moniz Institute of the Oswaldo Cruz Foundation, Bahia, Brazil;* [14]*Pediatric Liver, GI and Nutrition Centre and Mowat Labs, King's College Hospital NHS Trust, London, UK;* [15]*The Roger Williams Institute of Liver Studies, Faculty of Medicine & Life Sciences, King's College London, London, UK;* [16]*Human Pathology, Kanazawa University Graduate School of Medicine, Kanazawa, Japan;* [17]*Unidad Académica Gastroenterología, Hospital de Clínicas, Facultad de Medicina, Udelar, Montevideo, Uruguay;* [18]*Department of Pediatrics, Division of Pediatric Gastroenterology & Hepatology, Mayo Clinic, Rochester, Minnesota, USA;* [19]*William J. von Liebig Center for Transplantation and Clinical Regeneration, Rochester, Minnesota, USA;* [20]*Department of Pathology, University of California, San Francisco, California, USA;* [21]*Department of Pediatrics, Stravitz-Sanyal Institute for Liver Disease and Metabolic Health, Virginia Commonwealth University, Richmond, Virginia, USA;* [22]*Laboratory of Pathology, Center for Cancer Research, National Cancer Institute, Bethesda, Maryland, USA;* [23]*Internal Medicine and Hepatogastroenterology Department, Istanbul Health and Technology University, Istanbul, Turkiye;* [24]*Liver Disease Center of Integrated Traditional Chinese and Western Medicine, Zhongda Hospital, Medical School, Southeast University, Nanjing, China;* [25]*Department of Pathology, GB Pant Institute of Postgraduate Medical Education and Research, Delhi, India;* [26]*Division of Gastrohepatology, Professor Edgard Santos University Hospital, Federal University of Bahia, Salvador, Bahia, Brazil;* [27]*Department of Pathology and Laboratory Medicine, Emory University School of Medicine, Atlanta, Georgia, USA;* [28]*Department of Hepatology, Sir HN Reliance Foundation Hospital, Mumbai, Maharashtra, India;* [29]*Translational and Clinical Research Institute, Faculty of Medical Sciences, Newcastle University, Newcastle Upon Tyne, UK;* [30]*Department of Pathology, Aretaieion Hospital, National and Kapodistrian University of Athens, Athens, Greece;* [31]*Transplant Clinical Research Center, Columbia University, New York, New York, USA;* [32]*Department of Pediatrics, Division of Gastroenterology and Nutrition, University of Alberta, Edmonton, Alberta, Canada;* [33]*Faculté de Médecine de Tours et Hôpital Trousseau, CHRU de Tours, Centre de Référence Constitutif des Maladies Vasculaires du Foie, FILFOIE, ERN RARE-LIVER, Tours, France;* [34]*Institute of Pathology, Lausanne University Hospital and University of Lausanne, Lausanne, Switzerland;* [35]*Translational Hepatology Section, Liver Diseases Branch, National Institute of Diabetes and Digestive and Kidney Diseases, National Institutes of Health, Bethesda, Maryland, USA*

Abbreviations

AASLD, American Association for the Study of Liver Diseases; ALEH, Latin American Association for the Study of the Liver; APASL, Asian Pacific Association for the Study of the Liver; COST, European Cooperation in Science and Technology; EASL, European Association for the Study of the Liver; ESP, European Society of Pathology; ESPGHAN, European Society for Paediatric Gastroenterology, Hepatology and Nutrition; EURO-VALDI-NET, European Cooperation in Science and Technology (COST) Action on Vascular Liver Diseases; HVPG, hepatic venous pressure gradient; IPH, idiopathic portal hypertension; ISF, incomplete septal fibrosis; MASLD, metabolic dysfunction–associated steatotic liver disease; NASPGHAN, North American Society for Pediatric Gastroenterology, Hepatology and Nutrition; NCPF, noncirrhotic portal fibrosis; NRH, nodular regenerative hyperplasia; PSVD, porto-sinusoidal vascular disorder; PVT, portal vein thrombosis; SAB, Scientific Advisory Board; SC, Steering Committee; SGIHPBPs, Society of GI and HPB Pathologists of India; SOS, sinusoidal obstruction syndrome; VALDIG, Vascular Liver Disease Interest Group; WG, working group.

Author contributions

Virginia Hernandez-Gea, Pierre-Emmanuel Rautou, Valerie Paradis, Christine Sempoux, Laure Elkrief and Theo Heller contributed to study conception and design, acquisition of data, and data analysis and interpretation. Virginia Hernandez-Gea drafted the manuscript and Pierre-Emmanuel Rautou completed critical revisions. All authors contributed to review and approval of the final version.

Endorsing organizations

American Association for the Study of Liver Diseases, The Asian Pacific Association for the Study of the Liver, Asociación Latinoamericana para el Estudio del Hígado, Brazilian Society of Pathology, European Association for the Study of the Liver, European Reference Network for Rare and Complex Hepatological Diseases, European Society of Paediatric Gastroenterology, Hepatology and Nutrition, European Society of Pathology, Hans Popper Hepatopathology Society, North American Society for Pediatric Gastroenterology, Hepatology and Nutrition, The Japanese Society of Pathology, Société Africaine d'Hépato-Gastro-entérologie et d'Endoscopie digestive, and Society of Gastrointestinal and Hepatopancreato-biliary Pathologists of India.

Funding information

This research was supported in part by the Intramural Research Program of the National Institutes of Health (NIH). The contributions of David E. Kleiner and Theo Heller were made as part of their official duties as NIH federal employees, are in compliance with agency policy requirements, and are considered Works of the United States Government. However, the findings and conclusions presented in this paper are those of the authors and do not necessarily reflect the views of the NIH or the US Department of Health and Human Services. Virginia Hernandez-Gea is supported by FIS PI23/00997, funded by Instituto de Salud Carlos III (ISCIII) and co-funded by the European Union; Project EJP_RD (RiTA) AC23_2/00015, funded by ISCIII; and an AES 2024 Intensification grant with file code INT24/0000.

Conflicts of interest

Virginia Hernandez-Gea consults for Cook Medical. She is on the speakers' bureau for GORE Medical. Amal Aqul advises Mirum, Ipsen, and Sarepta Therapeutics. Angelo Di Giorgio consults for and advises Mirum, Ipsen, and Orchard Therapeutics. Sanjay Kakar consults for PathAI. Saul Karpen consults for Ipsen. Romil Saxena consults for Perspectum and AstraZeneca. The remaining authors have no conflicts to report.

Supplementary data

Supplementary data to this article can be found online at https://doi.org/10.1016/j.jhep.2026.04.030.

References

Author names in bold designate shared co-first authorship

[1] Wellcome Collection. Dell' anemia splenica/Guido Banti. n.d. Accessed February 28, 2026. https://wellcomecollection.org/works/qtcd8uk4/items?canvas=2.

[2] Shukla A, Rockey DC, Kamath PS, et al. Non-cirrhotic portal fibrosis/idiopathic portal hyper-tension: APASL recommendations for diagnosis and manage-ment. Hepatol Int 2024;18:1684–1711.

[3] Northup PG, Garcia-Pagan JC, Garcia-Tsao G, et al. Vascular liver disorders, portal vein thrombosis, and procedural bleeding in patients with liver disease: 2020 practice guidance by the American Association for the Study of Liver Diseases. Hepatology 2021;73:366–413.

[4] European Association for the Study of the Liver. EASL Clinical Practice Guidelines on vascular diseases of the liver. J Hepatol 2026;84:399–456.

[5] **Cazals-Hatem D**, **Hillaire S**, Rudler M, et al. Obliterative portal venopathy: portal hyper-tension is not always present at diagnosis. J Hepatol 2011;54:455–461.

[6] Guido M, Sarcognato S, Sonzogni A, et al. Obliterative portal venopathy without portal hypertension: an underestimated condition. Liver Int 2016;36:454–460.

[7] Barge S, Grando V, Nault JC, et al. Prevalence and clinical significance of nodular regenerative hyperplasia in liver biopsies. Liver Int 2016;36:1059–1066.

[8] De Gottardi A, Rautou PE, Schouten J, et al. Porto-sinusoidal vascular disease: proposal and description of a novel entity. Lancet Gastroenterol Hepatol 2019;4:399–411.

[9] de Franchis R, Bosch J, Garcia-Tsao G, et al. Baveno VII—renewing consensus in portal hypertension. J Hepatol 2022;76:959–974.

[10] Albayrak NE, Jain D, Torbenson M, et al. Porto-sinusoidal vascular disorder (PSVD): survey-based analysis of the usage and drawbacks of this newly proposed terminology. Hum Pathol 2025;166:105958.

[11] Sarin SK, Lohse AW, Kamath PS. Poor long-term outcome in patients with porto-sinusoidal vascular disease (PSVD): fact or disease misclassification. J Hepatol 2025;82:4–6.

[12] Burt AD, Gouw ASH, Callea F, et al. Making sense of "porto-sinusoidal vascular disorder": what does it mean for the pathologist and the patient? Liver Int 2025;45:e16196.

[13] EuroValdi. NetCost action CA23146. 2026. n.d. Accessed February 28, https://eurovaldinet.eu/.

[14] de Broucker C, Paradis V, Botero ML, et al. Liver biopsy quality criteria to exclude cirrhosis in case of suspicion of porto-sinusoidal vascular disorder. JHEP Rep 2026;8:101670.

[15] Sayadi A, Sempoux C, Gouw A, et al. Evidence based definition of major and minor histological criteria for the diagnosis of porto-sinusoidal vascular disorder (Abstract EASL 2026). J Hepatol 2026.

[16] Edilmar Alvarado-Tapias. SAT-344-YI Long-term out-come of sinusoidal obstruction syndrome secondary to hema-topoietic stem cell transplantation. J Hepatol 2025;82:S732.

[17] Di Giorgio A, Matarazzo L, Sonzogni A, et al. Paediatric porto-sinusoidal vascular disease: two different clinical phenotypes with subtle histolog-ical differences. Liver Int 2023;43:1523–1536.

[18] Franchi-Abella S, Fabre M, Mselati E, et al. Obliterative portal venopathy: a study of 48 children. J Pediatr 2014;165:190. 93.e2.

[19] Girard C, Laborde N, Marbach C. Porto-sinusoidal vascular disease: a pediatric study of 30 patients. J Pediatr Gastroenterol Nutr 2022;74:e132–e137.

[20] Nunes V, de Freitas LAR, de Freitas JR, et al. Obliterative portal venopathy: a neglected and probably misdiagnosed disease with peculiar etiology in South America. JGH Open 2022;6:904–909.

[21] Magaz M, Giudicelli-Lett H, Abraldes JG, et al. Porto-sinusoidal vascular liver disorder with portal hypertension: natural history and long-term outcome. J Hepatol 2025;82:72–83.

[22] Zhang Y, Xiong Q, Zhong Y, et al. Clinical characteristics and natural history of porto-sinusoidal vascular disease: a cohort study of 234 patients in China. Liver Int 2024;44:2329–2340.

[23] Olivas P, Soler-Perromat A, Tellez L, et al. Persistent varices in cured patients: understanding the role of hepatic venous pressure gradient. JHEP Rep 2024;6:101170.

[24] Magaz M, Giudicelli-Lett H, Nicoară-Farcău O, et al. Liver transplantation for porto-sinusoidal vascular liver disorder: long-term outcome. Transplantation 2023;107:1330–1340.

[25] Valdig. PSVD atlas. https://www.valdig.eu/psvd-atlas/. [Accessed 28 February 2026].

[26] Zuo C, Chumbalkar V, Ells PF, et al. Prevalence of histological features of idiopathic noncirrhotic portal hyper-tension in general population: a retrospective study of incidental liver biopsies. Hepatol Int 2017;11:452–460.

[27] Pugliese N, Ponziani FR, Cerini F, et al. Link between persistent, unexplained gamma-glutamyltransferase elevation and porto-sinusoidal vascular disorder. JHEP Rep 2024;6:101150.

[28] Moga L, Paradis V, Ferreira-Silva J, et al. Performance of spleen stiffness measurement to rule out high-risk varices in patients with porto-sinusoidal vascular disorder. Hepatology 2025;81:546–559.

Keywords: idiopathic portal fibrosis; nodular regenerative hyperplasia; noncirrhotic portal hypertension; portal hypertension; portosinusoidal vascular disorder.

Received 24 April 2026; accepted 24 April 2026; available online 27 May 2026