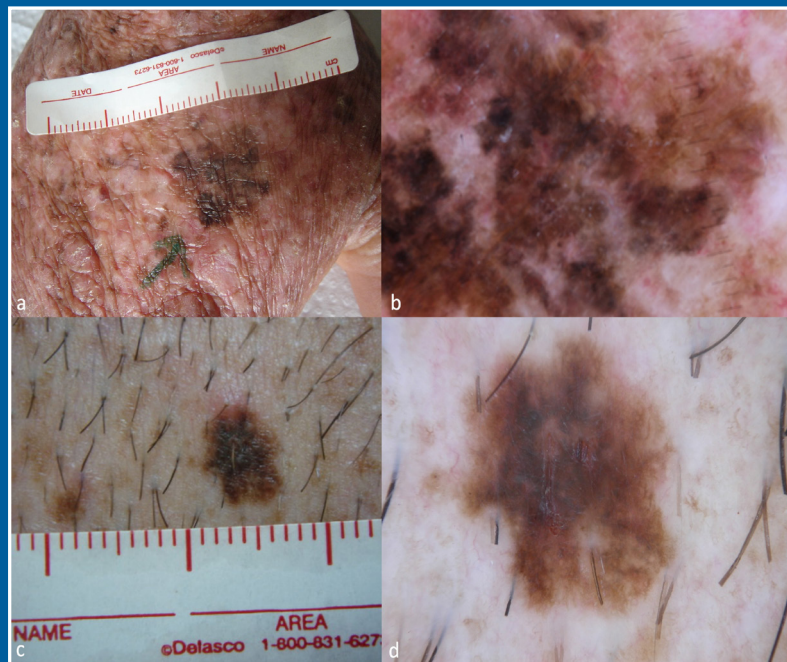


TURKISH JOURNAL OF DERMATOLOGY

VOLUME 19 • ISSUE 3 • SEPTEMBER 2025

www.turkjdermatol.com



An Official Publication of Turkish Society of Dermatology

EDITORIAL BOARD

Editor-in-Chief:

Prof. Dr. Murat Durdu,

Department of Dermatology, Başkent University Faculty of Medicine, Adana Dr. Turgut Noyan Application and Research Center, Adana, Türkiye
e-mail: sivandr@hotmail.com; muratdurdu44@yahoo.com

Associate Editors:

Prof. Dr. Sibel Doğan Günaydın M.D., M.Sc.

Department of Dermatology and Venereology, Hacettepe University Faculty of Medicine, Ankara, Türkiye
e-mail: sibel.dogan@hacettepe.edu.tr

Assoc. Prof. Aslan Yürekli

Department of Dermatology, University of Health Sciences Türkiye, Gülhane Training and Research Hospital, Ankara, Türkiye
e-mail: aslanyurekli03@hotmail.com

Assoc. Prof. Aşenur Botsali

Clinic of Dermatology and Venereology, University of Health Sciences Türkiye, Gülhane Training and Research Hospital, Ankara, Türkiye
e-mail: abotsali@hotmail.com

Editorial Board Members:

Prof. Dr. Necmettin Akdeniz

Department of Dermatology, Medeniyet University, Göztepe Training and Research Hospital, İstanbul, Türkiye
e-mail: drnakdeniz@gmail.com

Prof. Dr. Şebnem Aktan

Department of Dermatology, Dokuz Eylül University Faculty of Medicine, İzmir, Türkiye
e-mail: sebnem.aktan@deu.edu.tr

Prof. Dr. Güneş Gür Aksoy

Department of Dermatology, Ankara City Hospital, Ankara, Türkiye
e-mail: gunesgur@gmail.com

Prof. Dr. Melih Akyol

Department of Dermatology, Cumhuriyet University Faculty of Medicine, Sivas, Türkiye
e-mail: melakyol@gmail.com

Prof. Dr. Ali Abdul Hussein S. AL-Janabi

Department of Microbiology, University of Kerbala, Karbala, Iraq
e-mail: aljanabi_bio@yahoo.com

Prof. Dr. Erkan Alpsoy

Department of Dermatology, Akdeniz University Faculty of Medicine, Antalya, Türkiye
e-mail: ealpsoy@akdeniz.edu.tr

Prof. Dr. İlknur Kıvanç Altunay

Department of Dermatology, University of Health Sciences Türkiye, Şişli Etfal Training and Research Hospital, İstanbul, Türkiye
e-mail: ialtunay@gmail.com

Prof. Dr. İkbâl Esen Aydınğöz

Department of Dermatology, Kozyatağı Acıbadem Hospital, İstanbul, Türkiye
e-mail: aydingozi@yahoo.com

Prof. Dr. Can Baykal

Department of Dermatology, İstanbul University, İstanbul Faculty of Medicine, Ankara, Türkiye
e-mail: baykalc@istanbul.edu.tr

Prof. Dr. Kıymet Baz

Department of Dermatology, Mersin University Faculty of Medicine, Mersin, Türkiye
e-mail: drkbaz@hotmail.com

Prof. Dr. Nilgün Bilen

Department of Dermatology, Kocaeli University Faculty of Medicine, Kocaeli, Türkiye
e-mail: nilbilen@kocaeli.edu.tr

Prof. Dr. Emel Bülbül Başkan

Department of Dermatology, Uludağ University Faculty of Medicine, Bursa, Türkiye
e-mail: bbemel@uludag.edu.tr

Prof. Dr. Seher Bostancı

Department of Dermatology, Ankara University Faculty of Medicine, Ankara, Türkiye
e-mail: sbostanci@msn.com

Dr. Paulo Ricardo Criado

Alergoskin Alergia e Dermatologia SS Ltda
Santo Andre, Brasil
e-mail: prcriado@uol.com.br

Prof. Dr. Emine Derviş

Department of Dermatology, University of Health Sciences Türkiye, Haseki Training and Research Hospital, İstanbul, Türkiye
e-mail: eminedervis@hotmail.com

Prof. Dr. Özlem Dicle

Department of Dermatology, Liv Hospital, İstanbul, Türkiye
e-mail: kodicle@hotmail.com

Prof. Dr. Asena Çiğdem Dođramacı

Department of Dermatology, Mustafa Kemal University Faculty of Medicine, Hatay, Türkiye
e-mail: catahan85@yahoo.com

Prof. Dr. Gonca Elçin

Department of Dermatology, Hacettepe University Faculty of Medicine, Ankara, Türkiye
e-mail: goncaelcin@gmail.com

Prof. Dr. Tülin Ergun

Department of Dermatology, Marmara University Faculty of Medicine, İstanbul, Türkiye
e-mail: tulinerg@yahoo.com

Prof. Dr. Aylin Türel Ermertcan

Department of Dermatology, Manisa Celal Bayar University Faculty of Medicine, Manisa, Türkiye
e-mail: draylinturel@hotmail.com

Dr. Enzo Errichetti

Senior Consultant Dermatologist and Venereologist, Institute of Dermatology, University Hospital "Santa Maria della Misericordia", Udine, Italy
e-mail: enzoerri@yahoo.it

Prof. Dr. İlgen Ertam

Department of Dermatology, Ege University Faculty of Medicine, İzmir, Türkiye
e-mail: ilgenertam@gmail.com

Prof. Dr. Emel Fetil

Department of Dermatology, Dokuz Eylül University Faculty of Medicine, İzmir, Türkiye
e-mail: emel.fetil@deu.edu.tr

Prof. Dr. Özgür Emek Kocatürk Göncü

Department of Dermatology, Koç University School of Medicine, İstanbul, Türkiye
e-mail: emekozgur@yahoo.com

Prof. Dr. Harish Chander Gugnani

Meerut, India
e-mail: harishgugnani@yahoo.com

Prof. Dr. Ayşe Tülin Güleç

Department of Dermatology, Başkent University Faculty of Medicine, Ankara, Türkiye
e-mail: tulinogulec@hotmail.com

Prof. Dr. Mehmet Salih Gürel

Department of Dermatology, Medeniyet University, Göztepe Training and Research Hospital, İstanbul, Türkiye
e-mail: msgurel@gmail.com

Prof. Dr. Mehmet Harman

Department of Dermatology, Dicle University Faculty of Medicine, Diyarbakır, Türkiye
e-mail: mharman@dicle.edu.tr

Dr. Ayman Abdelmaksoud Elhaoseiny Ibrahim

Department of Dermatology, Dermatology and Leprology Hospital, Mansoura, Egypt
e-mail: behcet.behcet@yahoo.com

Prof. Dr. Nilşel İlter

Department of Dermatology, Gazi University Faculty of Medicine, Ankara, Türkiye
e-mail: nilselilter@gmail.com

Prof. Dr. Güliz İkizođlu

Department of Dermatology, Mersin University Faculty of Medicine, Mersin, Türkiye
e-mail: gikizoglu@yahoo.com

Prof. Dr. Işıl İnanır

Department of Dermatology, Manisa Celal Bayar University Faculty of Medicine, Manisa, Türkiye
e-mail: inanirisil@yahoo.com

Prof. Dr. Camila K. Janniger

Department of Dermatology, Rutgers New Jersey Medical School, New Jersey, USA
e-mail: camila.janniger@rutgers.edu

Prof. Dr. Ayşe Anıl Karabulut

Department of Dermatology, Kırıkkale University Faculty of Medicine, Kırıkkale, Türkiye
e-mail: dr.aa.karabulut@gmail.com

Prof. Dr. Ali Karakuzu

Department of Dermatology, Katip Çelebi University Faculty of Medicine, İzmir, Türkiye
e-mail: dr.karakuzu@gmail.com

Prof. Dr. Göksun Karaman

Department of Dermatology, Aydın Adnan Menderes University Faculty of Medicine, Aydın, Türkiye
e-mail: goksunkaraman@hotmail.com

Assoc. Prof. Selda Pelin Kartal

Department of Dermatology, Ankara Dışkapı Yıldırım Beyazıt Training and Research Hospital, Ankara, Türkiye
e-mail: pelin@dr.com

Dr. Pawel Pietkiewicz

Grater Poland Cancer Centre, General Oncology Surgery Clinic I, Poznań, Poland
e-mail: pietkiewicz.pp@gmail.com

Prof. Dr. Ayşe Kavak

Department of Dermatology, University of Health Sciences
Türkiye, Bakırköy Dr. Sadi Konuk Training and Research
Hospital, İstanbul, Türkiye
e-mail: ays_kavak@excite.com

Prof. Dr. Rebiay Apaydın Kıran

Department of Dermatology, Kocaeli University Faculty of
Medicine, Kocaeli, Türkiye
e-mail: rebiay@kocaeli.edu.tr

Prof. Dr. Rafet Koca

Department of Dermatology, Bülent Ecevit University Faculty of
Medicine, Zonguldak, Türkiye
e-mail: rafkoca@yahoo.com

Prof. Dr. Afet Akdağ Köse

Department of Dermatology, İstanbul University, İstanbul
Faculty of Medicine, İstanbul, Türkiye
e-mail: akose@istanbul.edu.tr

Prof. Dr. Osman Köse

Ankara, Türkiye
e-mail: drokose@yahoo.com.tr

Assoc. Prof. Adem Köşlü

İstanbul, Türkiye
e-mail: ademkoslu@gmail.com

Prof. Dr. Nihal Kundakçı

Department of Dermatology, Ankara University Faculty of
Medicine, Ankara, Türkiye
e-mail: nihalkundakci@hotmail.com

Prof. Dr. Rifkiye Küçüköğlü

Department of Dermatology, İstanbul University, İstanbul
Faculty of Medicine, İstanbul, Türkiye
e-mail: rsarica@istanbul.edu.tr

Prof. Dr. Ahmet Metin

Department of Dermatology, Ankara City Hospital, Ankara,
Türkiye
e-mail: ahmetin@gmail.com

Prof. Dr. Nahide Onsun

Department of Dermatology, Bezmialem University Faculty of
Medicine, İstanbul, Türkiye
e-mail: nonsun@bezmialem.edu.tr

Prof. Dr. Zerrin Öğretmen

Department of Dermatology, Onsekiz Mart University Faculty of
Medicine, Çanakkale, Türkiye
e-mail: zogretmen@gmail.com

Prof. Dr. Fezal Özdemir

İzmir, Türkiye
e-mail: ozdemirfezal@gmail.com

Prof. Dr. Şevki Özdemir

Department of Dermatology, Atatürk University Faculty of
Medicine, Erzurum, Türkiye
e-mail: sevkiozdemir@hotmail.com

Prof. Dr. Ayşe Şebnem Özkan

İzmir, Türkiye
e-mail: sebnem.ozkan50@gmail.com

Prof. Dr. Perihan Öztürk

Department of Dermatology, Sütçü İmam University Faculty of
Medicine, Kahramanmaraş, Türkiye
e-mail: drperihanozturk@hotmail.com

Prof. Dr. Ali Haydar Parlak

Department of Dermatology, Abant İzzet Baysal University
Faculty of Medicine, Bolu, Türkiye
e-mail: ahparlak@yahoo.com

Prof. Dr. Robert A. Schwartz

Rutgers New Jersey Medical School, New Jersey, USA
e-mail: roschwar@cal.berkeley.edu

Prof. Dr. Deniz Seçkin

Department of Dermatology, Başkent University Faculty of
Medicine, Ankara, Türkiye
e-mail: denizseckin50@gmail.com

Prof. Dr. Sedef Şahin

Department of Dermatology, Acıbadem Hospital, İstanbul,
Türkiye
e-mail: edef.sahin@acibadem.com.tr

Prof. Dr. Berna Şanlı

Denizli, Türkiye
e-mail: bernasanlier@gmail.com

Prof. Dr. Hatice Erdi Şanlı

Department of Dermatology, Ankara University Faculty of
Medicine, Ankara, Türkiye
e-mail: haticesanli1964@gmail.com

Prof. Dr. Ekin Bozkurt Şavk

Department of Dermatology, Adnan Menderes University Faculty
of Medicine, Aydın, Türkiye
e-mail: esavk@adu.edu.tr

Prof. Dr. Nilgün Şentürk

Department of Dermatology, Ondokuz Mayıs University Faculty
of Medicine, Samsun, Türkiye
e-mail: nilsenturk@yahoo.com

TURKISH JOURNAL OF DERMATOLOGY

Prof. Dr. Oktay Taşkapan

Department of Dermatology, Yeditepe University Faculty of Medicine, İstanbul, Türkiye
e-mail: oktaytaskapan@hotmail.com

Prof. Dr. Serap Utaş

Department of Dermatology, Acıbadem Fulya Hospital, İstanbul, Türkiye
e-mail: seraputas@gmail.com

Prof. Dr. İdil Ünal

Department of Dermatology, Ege University Faculty of Medicine, İzmir, Türkiye
e-mail: idil.unal@ege.edu.tr

Prof. Dr. Deniz Yücelten

Department of Dermatology, Marmara University, Pendik Training and Research Hospital, İstanbul, Türkiye
e-mail: aysedenizy@hotmail.com

Prof. Dr. Dedee Murrell (Avustralya)

Department of Dermatology, St. George Hospital, Gray St, Kogarah Sydney, Australia
e-mail: d.murrell@unsw.edu.au

Assoc. Prof. Mariano Suppa (Belçika)

Hôpital Erasme - Department of Dermatology, Université Libre de Bruxelles, Brussels, Belgium
e-mail: dr.marianosuppa@gmail.com

Prof. Amor Khachemoune MD, FAAD, FACMS, (America)

Dermatologist, Mohs Micrographic Surgeon & Dermatopathologist, State University of New York, Brooklyn, New York, USA
e-mail: amorkh@gmail.com

Prof. Dr. Lidia Rudnicka (Polonya)

Department of Dermatology, Medical University of Warsaw, Warsaw, Poland
e-mail: lidiarudnicka@gmail.com

Prof. Dr. Antonella Tosti

Fredric Brandt Endowed Professor, Dr. Phillip Frost Department of Dermatology and Cutaneous Surgery, University of Miami, U.S.
e-mail: ATosti@med.miami.edu

Dr. Christoph R. Löser

(Dermatosurgery, Nail Surgery, History of Dermatology)
Leitender Oberarzt Hautklinik, Hauttumorzentrum Klinikum Ludwigshafen Bremsenstr, Ludwigshafen, Germany
e-mail: loeserc@klilu.de

Assoc. Prof. Marija Buljan

Department of Dermatology, Sestre Milosrdnice University Hospital Center, Zagreb, Croatia
e-mail: buljan.marija@gmail.com

Please refer to the journal's webpage (www.turkjdermatol.com) for "Ethical Policy" and "Instructions to Authors".

The editorial and publication process of the Turkish Journal of Dermatology are shaped in accordance with the guidelines of the ICMJE, WAME, CSE, COPE, EASE, and NISO. Turkish Journal of Dermatology is indexed in **Emerging Sources Citation Index, SCOPUS, EMBASE/ Excerpta Medica, Scimago Journal Ranking, Baidu Scholar, CNKI (China National Knowledge Infrastructure), EBSCO, Ex Libris – Primo Central, Turk Medline, Google Scholar, Hinari, Infotrieve, ProQuest, TDNet, Turkey Citation Index and Wanfang Data.**

The journal is published online.

Owner: Ertan Yılmaz on behalf of the Turkish Dermatology Society

Responsible Manager: Murat Durdu

Publisher Contact

Address: Molla Gürani Mah. Kaçamak Sk. No: 21/1

34093 İstanbul, Türkiye

Phone: +90 (530) 177 30 97

E-mail: info@galenos.com.tr/yayin@galenos.com.tr

Web: www.galenos.com.tr Publisher Certificate Number: 14521

Printing Date: September 2025

E-ISSN: 1307-7635

International scientific journal published quarterly.

CONTENTS

ORIGINAL ARTICLES

- 118 Human Papillomavirus (HPV) Awareness and Vaccine Hesitancy Among Medical Students: A Cross-Sectional Study on Knowledge, Stigma, and Preventive Behavior**
Elif Afacan Yıldırım, Tülay Nur Kızık; İstanbul, Türkiye
- 126 Benchmarking Large Language Models on the Turkish Dermatology Board Exam: A Comparative Multilingual Analysis**
Ahmet Uğur Atılan, Niyazi Çetin; Denizli, Türkiye
- 134 Dermoscopy-Guided Surveillance in Xeroderma Pigmentosum: A Retrospective Analysis**
Göktürk Oraloğlu, Nilay Duman, Banu Yaman, Taner Akalın, Işıl Karaarslan; İstanbul, İzmir, Türkiye
- 138 Monocyte-To-Lymphocyte Ratio May Be a Clue to Understand Underlying Cause of Pruritus in Chronic Kidney Disease**
Neslihan Demirel Ögüt, Orçun Valerian Çetin, Nilay İnci, Zelal Adıbelli, Ender Hür; Uşak, Türkiye
- 145 Social Appearance Anxiety and Its Impact on Patients with Verruca Vulgaris: A Comparative Study with Healthy Controls**
Mustafa Tümtürk, Nazlı Caf, Natallia Kruk, Faruk Kurhan; İstanbul, Van, Türkiye; Minsk, Belarus
- 150 Risk Factors Associated with Comorbidities and Complications in Patients with Herpes Zoster Ophthalmicus: A Retrospective Analysis**
Elif Bal Avcı, Buğra Burç Dağtaş, Ayşe Esra Koku Aksu, Asude Kara Polat, Vildan Manav, Mehmet Salih Gürel; Edirne, İstanbul, Türkiye
- 158 The Evolution of Tzanck Smear Publications: A Bibliometric Analysis with Research Trends and Global Productivity**
Esra Altay, Selami Aykut Temiz, İlkay Özer, Munise Daye, Recep Dursun; Konya, Türkiye
- 169 The Relationship Between Depression Levels and Suicide Risk in Pediatric Patients with Alopecia Areata and the Oxidant-Antioxidant Balance**
Dilşad Yıldız Miniksar, Emine Çölgeçen, Ayşe Yeşim Göçmen, Mahmut Kılıç; Ankara, Yozgat, Türkiye

CASE REPORTS

- 178 A Unique Overlap of Scarring and Non-Scarring Alopecia in Primary Cutis Verticis Gyrata**
Batuhan Mustafa Demir, Serkan Yazıcı, Şaduman Balaban Adım; Bursa, Türkiye
- 182 An Unusual Presentation of Cutaneous Mucormycosis Mimicking Recalcitrant Dermatophytosis: A Case Report**
Sümeyye Aktaş, Selami Aykut Temiz, Selin Uğraklı, Hilal Sena Çiftci; Konya, Türkiye

Dermoscopy-Guided Surveillance in Xeroderma Pigmentosum: A Retrospective Analysis

© Göktürk Oraloğlu¹, © Nilay Duman², © Banu Yaman³, © Taner Akalın³, © Işıl Karaarslan²

¹Department of Dermatology, İstanbul Health and Technology University Faculty of Medicine, İstanbul, Türkiye

²Department of Dermatology, Ege University Faculty of Medicine, İzmir, Türkiye

³Department of Pathology, Ege University Faculty of Medicine, İzmir, Türkiye

Abstract

Aim: Xeroderma pigmentosum (XP) is a life-threatening disease characterized by high rates of skin cancers. Therefore, it is important to establish key guidelines for the follow-up of these patients to detect skin cancers, particularly melanoma, at an early stage.

Materials and Methods: This is a retrospective study that includes the analysis of the follow-up findings and medical records of XP patients who were followed up with whole-body skin examination, dermoscopic examination, and whole-body photographing between 2003 and 2021 in the Dermato-Oncology unit of Ege University Department of Dermatology.

Results: Of the 19 patients, 10 were male and 9 were female. The youngest patient was 5 years old, while the oldest patient was 64 years old. A total of 234 lesions were excised from these patients. Seventeen melanomas were excised, including 11 *in situ*, with a Breslow thickness of less than 1 mm. The highest Breslow scores belong to patients who missed their appointments or did not receive follow-up care previously.

Conclusion: It was observed that regular full-body skin examinations, whole-body photography, and dermoscopic monitoring performed at 3-month intervals in XP patients are helpful in detecting skin malignancies at an early stage and preventing unnecessary excisions.

Keywords: Xeroderma pigmentosum, dermoscopy, basal cell carcinoma, squamous cell carcinoma, melanoma

INTRODUCTION

Xeroderma pigmentosum (XP) is an autosomal recessive genetic disease that affects the DNA repair system necessary to repair DNA damage caused by ultraviolet radiation.¹ It is characterized by marked photosensitivity, facial freckles that appear before the age of 2, ocular findings including keratitis and photophobia, and an early onset of skin malignancies such as basal cell carcinoma (BCC), squamous cell carcinoma (SCC), and melanoma.² In XP patients under 20 years of age, the risk of developing non-melanoma skin cancer is 10,000 times higher, while the risk of developing melanoma is 2,000 times greater compared to the general population.³ Due to the

high rates of skin cancers, this disease can be life-threatening, and the prognosis depends on the patient's awareness of the disease, sun protection measures and early diagnosis of skin cancers.⁴ However, widespread actinic damage characterized by multiple lentigines, actinic keratoses, and poikiloderma complicates the diagnosis of skin tumors in these patients. In this context, dermoscopy serves as a non-invasive tool that aids in the early diagnosis of skin tumors in these individuals.⁵ Few reports in the literature discuss the role of dermoscopic follow-up in the early detection of skin tumors in XP patients.^{5,6} In our study, we aimed to highlight the importance of dermoscopic follow-up for the early detection of skin tumors in XP patients.

Submission: 06-May-2025

Acceptance: 08-Jun-2025

Web Publication: 10-Sep-2025

Access this article online

Quick Response Code:



Website:

www.turkjdermatol.com

DOI:

10.4274/tjd.galenos.2025.46330

Address for correspondence: Nilay Duman, MD,

Department of Dermatology, Ege University Faculty of Medicine, İzmir, Türkiye

Email: nilyduman@gmail.com

ORCID ID: 0000-0001-6295-211X



This is an open access journal, and articles are distributed under the terms of the Creative Commons Attribution-NonCommercial 4.0 International License, which allows others to remix, tweak, and build upon the work non-commercially, as long as appropriate credit is given.

How to cite this article: Oraloğlu G, Duman N, Yaman B, Akalın T, Karaarslan I. Dermoscopy-guided surveillance in xeroderma pigmentosum: a retrospective analysis. *Turk J Dermatol.* 2025;19(3):134-137.

MATERIALS AND METHODS

Our study ethical approval was obtained from the Ege University Medical Research Ethics Committee (approval number: 21-11.1T/46, date: 18.11.2021). Consent was obtained to analyze patients' medical records for the study. Patients with XP underwent whole-body skin examinations, dermoscopic examinations, and whole-body photographs between 2003 and 2021 at the Dermato-Oncology unit of Ege University Department of Dermatology. Patients were followed up every three months with total body photographing whole body dermoscopic examination. In the present study, we analyzed the follow-up findings and medical records of these patients. We noted their age, sex, follow-up duration, and the pathology reports of excised skin tumors, and melanocytic lesions.

Statistical Analysis

All data were analyzed descriptively. Continuous variables were summarized as mean \pm standard deviation, and categorical variables were presented as frequencies and percentages. No comparative statistical tests were performed due to the descriptive and retrospective design of the study.

RESULTS

Patients' Demographics Features

A total of 19 XP patients were followed up between 2003 and 2021 in the Dermato-Oncology Unit of the Department of Dermatology at Ege University. Fourteen of these patients attended follow-up visits regularly, while five patients did not attend consistently for unknown reasons. Of the 19 patients, 10 were male and nine were female. The youngest patient was 5 years old, and the oldest patient was 64 years old. The mean age was 24.97 (± 15.07), with the mean age for male patients being 22.7 (± 12.29) and for female patients being 27.4 (± 17.31). A total of 234 lesions were excised from these patients.

Skin Cancer Development Age

The earliest age of BCC development was 7, the SCC development age was 6, and melanoma development was 8. The mean ages of BCC, SCC, and melanoma were 20.15 [± 13.56 , minimum (min.): 7, maximum (max.): 59], 23.22 (± 12.42 , min.: 6, max.: 47), and 18.3 (± 7.9 , min.: 8, max.: 28), respectively.

Skin Cancer Characteristics

Basal Cell Carcinoma

In total, 139 BCCs were excised. The histopathological types of these BCCs included 38 nodular, 12 superficial, 9 micronodular, 8 infiltrative, 6 noduloulcerative, 6 ulceroinfiltrative, 3 ulcerative, 2 morpheaform, 7 mixed type, and 1 bowenoid type. The type was not specified in the pathology report for 47 cases. The highest number of BCCs in a single patient was found to be 56, followed by 42. Additionally: a 64-year-old female patient who had been followed up for 10 years and had a single instance of BCC was remarkable due to her generally stable health status.

Squamous Cell Carcinoma

A total of 44 SCCs were excised, 6 of which were located in the lip mucosa and the others were cutaneous. Fifteen of these SCCs were *in situ*, 9 were well-differentiated, 5 were moderately differentiated, 8 were poorly differentiated, 4 were microinvasive, 1 was keratoacanthoma-like type, and the type of 2 was unspecified in the pathology report. In addition, five conjunctival SCCs, three corneal SCCs *in situ*, and one high-grade squamous intraepithelial neoplasia in the cornea were excised by ophthalmologists.

Melanoma

Only 5 of 19 XP patients developed melanoma during the follow-up. A total of 17 melanomas were excised, five of which were excised from a single patient. Among these, 11 melanomas were *in situ*, 5 of which were lentigo maligna. The Breslow thicknesses of the other patients were as follows, in order from the lowest to the highest: 0.27 mm, 0.9 mm, 0.93 mm, 2.3 mm, 5.6 mm, and 15 mm. One patient was referred to our unit for the first time with melanoma metastasis in a lymph node of unknown origin; prior to this, he had never been followed by dermoscopy.

Other Malignant and Benign Tumors

Other excised malignant tumors included 5 atypical melanocytic proliferations, 1 atypical fibroxanthoma, 1 melanocytic tumor with regressive changes, 1 melanocytic tumor of uncertain malignant potential, 3 angiosarcomas, and 1 vascular tumor with uncertain malignant potential. A total of 22 benign lesions were excised, including 6 compound nevi, 6 junctional nevi, 3 dysplastic nevi, 2 lentiginous nevi, 2 dermal nevi, 1 dermal melanocytic hamartoma, 1 lentiginous hyperplasia, and 1 spitz nevus.

DISCUSSION

The literature on the role of dermoscopic follow-up in XP patients is limited. To the best of our knowledge, there are only two reports regarding dermoscopic follow-up in XP patients. Firstly, Malvey et al.⁵ reported dermoscopic findings of melanoma and non-melanoma skin cancers in two siblings who were followed for nearly 5 years. They suggested that distinguishing between benign and malignant tumors based solely on clinical examination is difficult, but dermoscopy aids in deciding on excision and helps detect melanoma at an early stage.

Green et al.⁶ demonstrated that an XP patient followed for 23 years developed 38 primary melanomas, SCCs, and 70 BCCs during follow-up. They also stated that none of the melanomas in this patient exhibited deep local invasion or metastasis. The authors monitored this patient with a whole-body skin examination, whole-body photographs, and dermoscopic assessments at 6-week intervals. They noted that many new melanomas were detected within 6 weeks. Thus, the authors recommended combining whole-body skin examination, photography, and dermoscopy at short intervals in the management of XP patients.

In the present study, most cases were detected at the *in situ* stage in both SCCs and melanomas (Figure 1). Additionally, many melanomas were identified while still at a thin Breslow thickness. The patient with the highest Breslow thickness had not been previously followed up and was referred to the Dermato-Oncology unit by plastic surgery. This finding supports the crucial role of regular patient follow-up through total body examinations, total body photography,

dermoscopic monitoring, and dermoscopic photography of suspicious skin lesions for the early detection of melanomas. Although the diagnostic accuracy of dermoscopy was not evaluated quantitatively in this retrospective study, all excised melanomas exhibited dermoscopic features suggestive of malignancy, such as asymmetric pigmentation, atypical network, and irregular streaks. Dermoscopy was instrumental in selecting lesions for excision.

Green et al.⁶ recommended follow-up at 6-week intervals. However, our study results indicate that follow-up performed at 3-month intervals is also sufficient to detect melanoma in their early stage. Additionally, follow-up intervals can be adjusted based on the frequency of skin cancer and suspicious skin lesions in the patient, provided the patient adequately complies with sun protection measures. It was noted that the patient with melanoma, having a Breslow thickness of 5.6 mm, did not seek examination for a long time, and consequently, the lesion reached this stage. Additionally, it was noted that this same patient had the highest number of melanomas and BCCs in our series; and they frequently delayed appointment dates and did not comply with sun protection recommendations. This serves as a unique example of how the patient's adherence to regular follow-up and sun protection influences early melanoma diagnosis.

The total number of benign lesions excised from the patients was 22, with some being congenital, others removed due to atypical criteria, and changes during follow-up, and some excised alongside the malignant tumor as they were located near it (Figure 2). It was observed that a total of 76 benign lesions were excised at the external center before the patient, who began to be followed up at the age of 27, was admitted.

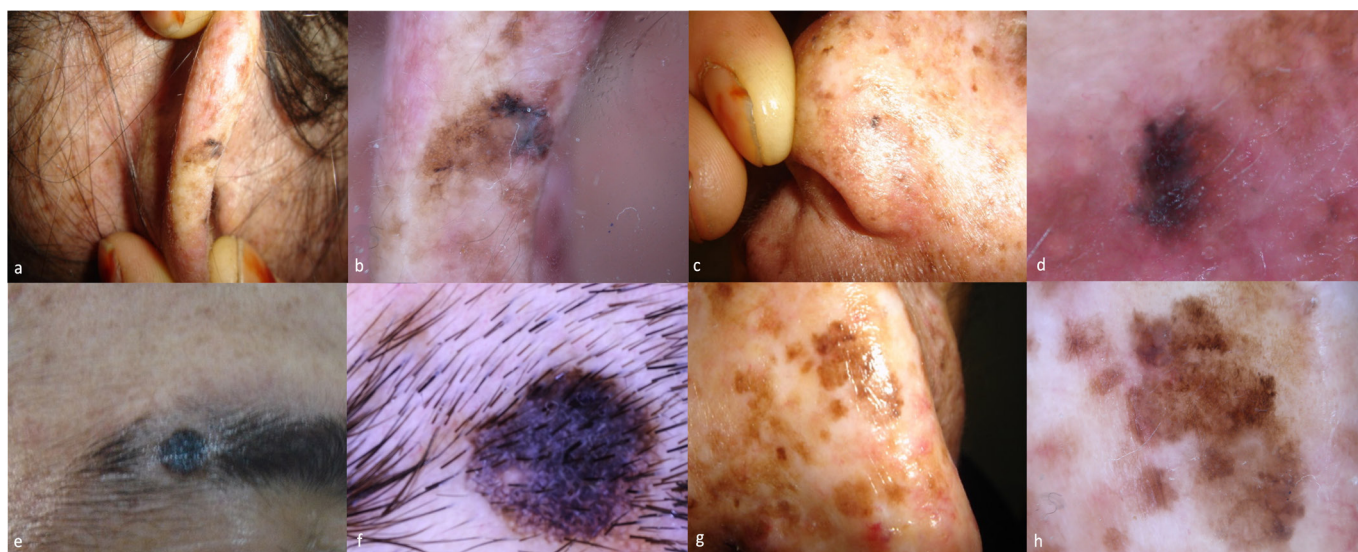


Figure 1. Clinical and dermoscopic pictures of (a, b) an *in situ* melanoma on the ear helix, (c, d) a tiny lentigo maligna on the patient's nose, (e, f) a sneaky melanoma (stage T1B) hiding behind thick eyebrows, and (g, h) lentigo maligna on the patient's nose

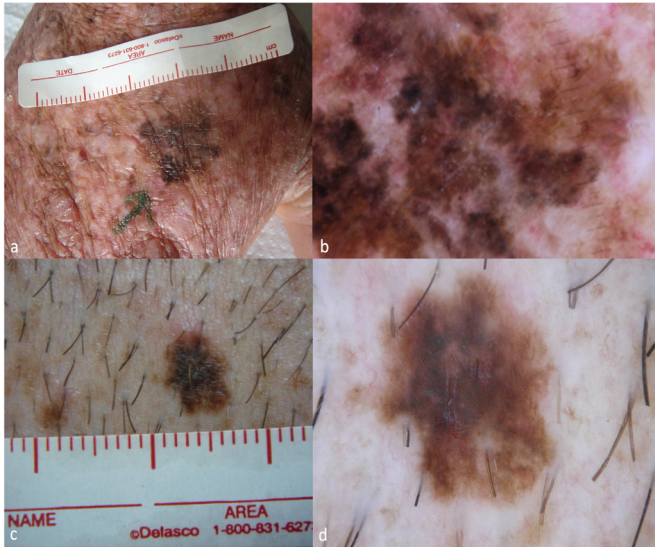


Figure 2. (a, b) Clinical and dermoscopic images of lentiginous hyperplasia mimicking melanoma; (c, d) An “ugly duck” lesion was found to be a dysplastic nevus on histopathology

These excision numbers for a single patient are significantly higher than our total number of melanocytic lesion excisions across all patients under follow-up, and highlight the importance of dermoscopic follow-up in reducing excision rates among these patients. Preventing unnecessary excisions is important in reducing the cost and undesirable cosmetic outcomes associated with redundant surgical procedures. Therefore, decline in the quality of life for patients is prevented.

Study Limitations

One important limitation of this study is the lack of genetic subtyping of XP patients. Due to the retrospective design and the long duration of follow-up (starting in 2003), routine genetic testing was not performed in most cases. As a result, genotype-phenotype correlations could not be assessed. Future prospective studies incorporating genetic data may help clarify subtype-specific cancer risks in XP.

CONCLUSION

Our patient series shows that regular full-body skin examinations, whole-body photographs, and dermoscopic monitoring performed at three-month intervals in XP patients

are crucial for detecting skin malignancies at an early stage and preventing unnecessary excisions in these patients.

Ethics

Ethics Committee Approval: Ethical approval was obtained from the Ege University Medical Research Ethics Committee (approval number: 21-11.1T/46, date: 18.11.2021).

Informed Consent: Consent was obtained to analyze patients’ medical records for the study.

Footnotes

Authorship Contributions

Concept: G.O., N.D., B.Y., T.A., I.K., Design: G.O., N.D., B.Y., T.A., I.K., Data Collection or Processing: G.O., N.D., B.Y., T.A., I.K., Analysis or Interpretation: G.O., N.D., I.K., Literature Search: G.O., N.D., I.K., Writing: G.O., N.D., I.K.

Conflict of Interest: The authors declared that they have no conflict of interest.

Financial Disclosure: The authors declared that this study received no financial support.

REFERENCES

1. Zhang J, Cheng R, Yu X, Sun Z, Li M, Yao Z. Expansion of the genotypic and phenotypic spectrum of xeroderma pigmentosum in Chinese population. *Photodermatol Photoimmunol Photomed*. 2017;33(1):58-63.
2. Tamura D, DiGiovanna JJ, Khan SG, Kraemer KH. Living with xeroderma pigmentosum: comprehensive photoprotection for highly photosensitive patients. *Photodermatol Photoimmunol Photomed*. 2014;30(2-3):146-152.
3. Zhang N, Fu X, Chen X, Chen L, Wang M. Variant subtype of xeroderma pigmentosum with multiple basal cell carcinomas diagnosed in a Chinese woman. *Photodermatol Photoimmunol Photomed*. 2021;37(2):161-164.
4. Canfield M, Norton S, Walburn J, Morrison-Bowen N, Sainsbury K, Araujo-Soares V, Sarkany R, Weinman J. Facial photoprotection in xeroderma pigmentosum (XP) patients: validation of a new self-reported questionnaire of adherence. 2020;36(2):118-125.
5. Malvey J, Puig S, Martí-Laborda RM. Dermoscopy of skin lesions in two patients with xeroderma pigmentosum. *Br J Dermatol*. 2005;152(2):271-278.
6. Green WH, Wang SQ, Cognetta AB Jr. Total-body cutaneous examination, total-body photography, and dermoscopy in the care of a patient with xeroderma pigmentosum and multiple melanomas. *Arch Dermatol*. 2009;145(8):910-915.