

Retrospective Analysis of Outcomes Following Expandable Titanium Cage and Iliac Graft Applications in Patients Undergoing Corpectomy for Cervical Spinal Canal Stenosis

✉ Hüseyin Demir¹, ✉ Nafiye Şanlıer²

¹Istanbul Health and Technology University Faculty of Medicine, Department of Neurosurgery, İstanbul, Türkiye

²University of Health Sciences Türkiye, İstanbul Training and Research Hospital, Clinic of Neurosurgery, İstanbul, Türkiye

ABSTRACT

Introduction: This study aimed to compare the clinical and radiological outcomes of iliac crest autografts and expandable titanium cages in anterior cervical column reconstruction among patients undergoing cervical corpectomy for cervical spinal stenosis.

Methods: A retrospective analysis of 93 patients who underwent anterior cervical corpectomy between 2016 and 2023 was conducted; 61 were treated with iliac grafts and 32 with expandable cages. Clinical efficacy was assessed using the modified Japanese Orthopaedic Association (mJOA) score, while radiological outcomes were evaluated by measuring cervical lordosis (C2-C7 Cobb angle), intervertebral height, and fusion status, three months post-surgery. Complications, operative duration, and revision surgery rates were also analysed.

Results: Both the iliac graft and cage groups demonstrated significant postoperative improvements in mJOA scores ($p < 0.001$). The iliac graft group exhibited superior early correction of cervical kyphosis, with the Cobb angle increasing from 3.17° to 9.12° ($p < 0.001$), compared with the cage group's increase from 0.99° to 5.83° ($p = 0.025$). Cervical alignment remained more stable over time in the iliac graft group. Complication rates were comparable between the groups; however, graft displacement occurred more frequently in the iliac graft group. In contrast, cage malposition occasionally necessitated revision surgery.

Conclusion: Both iliac grafts and expandable cages are effective for anterior cervical reconstruction, yielding comparable clinical outcomes and complication rates. Iliac grafts may be better suited for achieving immediate postoperative correction and maintaining stable long-term alignment. The choice of surgical technique should take into account specific patient needs and the distinct risk profiles associated with each method.

Keywords: Cervical spinal canal stenosis, cervical corpectomy, iliac graft, expandable titanium cage

Introduction

First described in the 1950s, anterior approaches to the cervical spine have gained widespread acceptance as effective methods for treating cervical spinal disorders (1). These methods provide a direct approach to anteriorly located lesions, facilitating restoration of sagittal alignment and decompression. When lesions involve multiple levels or extend posteriorly into the vertebral body, a corpectomy or vertebrectomy, including the adjacent discs, may be required. Reconstruction of the anterior column requires either an implant or a bone graft. The most suitable vertebral body replacement should provide the following advantages: anterior support resistant to axial loads, deformity correction capability, primary stability, and an extended contact surface with adjacent vertebral bodies to promote rapid fusion and prevent micromotion (2).

Until recently, autologous bone grafts were the most frequently used replacements following corpectomy. However, 20-30% of patients experience donor-site complications following iliac bone grafting. These complications include hematoma, infection, neurological injury, abdominal herniation, iliac crest fracture, and persistent pain or discomfort at the donor site (3). Elderly patients often present with insufficient iliac bone stock due to age-related decreases in bone mass (4). To eliminate the need for harvesting large structural bone and to prevent donor site complications, titanium mesh cages -rigid constructs that can be filled with autologous local bone- have been developed.

Numerous studies have demonstrated that titanium cages, particularly in patients with multilevel involvement, are safe and effective in the treatment of degenerative cervical diseases, yielding favourable long-term clinical and functional outcomes (5). However, few studies



Address for Correspondence: Hüseyin Demir MD, İstanbul Health and Technology University Faculty of Medicine, Department of Neurosurgery, İstanbul, Türkiye
E-mail: hdemirrr@outlook.com ORCID ID: orcid.org/0000-0002-5263-2793

Cite this article as: Demir H, Şanlıer N. Retrospective analysis of outcomes following expandable titanium cage and iliac graft applications in patients undergoing corpectomy for cervical spinal canal stenosis. Istanbul Med J. 2026; 27(1): 20-6

Received: 10.09.2025

Accepted: 18.12.2025

Publication Date: 02.02.2026



©Copyright 2026 by the University of Health Sciences Türkiye, İstanbul Training and Research Hospital/Istanbul Medical Journal published by Galenos Publishing House.
Licensed under a Creative Commons Attribution-NonCommercial-NoDerivatives 4.0 (CC BY-NC-ND) International License

comparing the safety and efficacy of titanium cages have been published, despite their widespread use. Radiographic assessment of fusion is more complex when titanium cages are used. Furthermore, vertebral endplate weakness increases the need for screw fixation, which in turn raises the risk of cage subsidence. A retrospective study by Chou et al. (6) reported that titanium cages were significantly less effective than iliac bone-dependent fusion, with a fusion rate of only 45.5% one year postoperatively. However, several other studies have shown that fusion rates and clinical outcomes were comparable between patients who underwent discectomy and fusion procedures with either iliac bone grafts or titanium cages (3,7). This retrospective analysis compared the outcomes of titanium cage use and iliac crest autograft use in cervical decompression and fusion procedures. We present the clinical and radiological outcomes of 93 patients with cervical spinal stenosis who underwent cervical corpectomy followed by reconstruction using either an expandable cage or an iliac graft. Neurological and functional outcomes were evaluated in patients with cervical degenerative disc disease who were treated using the anterior approach. Clinical outcomes were evaluated using the modified Japanese Orthopaedic Association (mJOA) score, and cervical lordosis, intervertebral height, and fusion status were assessed by X-ray or magnetic resonance imaging (MRI).

Methods

In this study, we retrospectively analysed data from 93 patients of both sexes, aged 18-90 years who were diagnosed with cervical spinal stenosis and admitted to the neurosurgery department between 2016 and 2023. The study was approved by the Tekirdağ Dr. İsmail Fehmi Cumalıoğlu City Hospital Clinical Research Ethics Committee (approval number: 99, date: 19.04.2024). This multicenter study was conducted in two departments (İstanbul Training and Research Hospital, Fatih Sultan Mehmet Training and Research Hospital).

Follow-up data and imaging studies of patients with cervical spinal stenosis who underwent anterior reconstruction using either iliac grafts or expandable cages were evaluated. Clinical evaluation included neurological examination and assessment of the mJOA score. mJOA scores were recorded preoperatively and three months postoperatively. Fusion and graft subsidence were evaluated radiologically using computed tomography (CT) and plain radiography. In addition, patient age, sex, Cobb angle correction at the reconstruction site, MRI signal changes, length of hospital stay, operative time, complications, spinal level of complications, treatment methods, and types of revision surgery were analysed.

Inclusion Criteria

Patients who underwent anterior column reconstruction for cervical spinal stenosis using either an iliac graft or an expandable cage were included in the study. Indications for anterior column reconstruction included pathological fractures with greater than 50% loss of vertebral body height, severe mechanical neck pain, and resection of more than 50% of the vertebral body. Patients who did not require anterior column reconstruction were excluded from the study.

Clinical Evaluation

Age, sex, duration of symptoms (preoperative clinical course), and initial functional status (preoperative mJOA score) were among the clinical variables examined for prognostic evaluation. Clinical outcomes and the benefits of surgical intervention were assessed using the modified mJOA scale and the postoperative functional recovery (PFR) rate (8).

Radiologic Assessment

Radiological evaluations were performed for each patient preoperatively, immediately postoperatively (before hospital discharge), and three months after surgery. Serial radiographs of the operated segment were used to evaluate spinal stability and the state of fusion. Postoperative CT scans of the affected region were obtained to document the positions of the cage and screws and to assess the extent of spinal fusion and decompression. Kyphotic deformity was evaluated on lateral radiographs of the cervical spine using the Cobb angle. The Cobb angle was measured between the superior endplate of the upper vertebra, where the corpectomy was performed, and the inferior endplate of the lower vertebra. The kyphotic angle was measured preoperatively, immediately postoperatively, at three months, and at final follow-up (range, 13-82 months; mean, 24 months). In this study, early postoperative (three-month) radiological outcomes were analysed for all patients, whereas long-term follow-up data were available for a subset of cases and used to assess maintenance of cervical alignment and fusion stability. The height of the reconstructed segment, defined as the distance between the inferior endplate of the upper vertebra and the superior endplate of the lower vertebra, was measured on lateral radiographs. All patients underwent CT and X-ray imaging three months postoperatively to assess potential cage displacement, subsidence, stability, and fusion. Determining fusion can be challenging in the presence of anterior cervical instrumentation.

Functional Assessment

The mJOA functional disability scale was used for preoperative and three-month postoperative assessments. The PFR rate was calculated using the formula proposed by Hirabayashi et al. (9) based on the pre- and postoperative mJOA scores.

$$\text{PFR (\%)} = \frac{(\text{Postoperative mJOA} - \text{preoperative mJOA})}{(18 - \text{Preoperative mJOA})} \times 100$$

Operation Procedure

Records of 93 patients who underwent single-level (n=60) or double-level (n=33) cervical corpectomy were analysed. Corpectomy types are presented in Table 1. An anterior approach was used to perform a cervical corpectomy; in some cases, additional posterior fixation was required to achieve optimal stability. The median duration from symptom onset to surgery was 12 months (range: 1-120 months). The median operative time was 4 hours (range: 2-8 hours), and the median length of hospital stay was 3 days (range: 1-60 days).

Expandable-cage reconstruction was performed using the Alton Sapimed Onspine® cylindrical titanium mesh cage following corpectomy (n=32). Great care was taken to preserve the bony endplates as much as possible during endplate preparation following corpectomy. The superior and

inferior ends of the cage were trimmed to match the sagittal contours of the adjacent vertebral endplates. Bone chips containing demineralized bone matrix and synthetic bone allograft were placed within and around each cage, both anteriorly and laterally. In these cases, autograft material was harvested from the iliac crest and the resected vertebral body. After placement of the anterior plate, controlled distracting forces were applied to correct the kyphotic deformity.

For iliac graft harvesting (n=61), after cutting the cortical tables of the iliac crest bilaterally with an osteotome or a power saw, a cortical graft of the desired size was harvested. The graft was then carefully elevated using a broad osteotome with gentle strokes. Continuous irrigation with room-temperature saline was used to prevent thermal injury and overheating.

Follow-up

Clinical examinations were performed preoperatively, during the early postoperative period (before discharge), and at least one year after surgery. Routine follow-up examinations were conducted every three months.

Statistical Analysis

Comparisons between the iliac graft and cage groups were performed using independent-sample tests, depending on the distribution of the data. Normality of continuous variables was assessed using the Shapiro-Wilk test. Depending on the results of normality tests, the Student's t-test or the Mann-Whitney U test was used for continuous variables, and the chi-square test was used for categorical variables. Paired analyses were conducted using the paired t-test or the Wilcoxon signed-rank test where appropriate. Descriptive statistics were used to summarize clinical and

demographic characteristics. All statistical analyses were performed using SPSS Statistics for Mac, version 29.0 (IBM Corp., Armonk, NY, USA), and statistical significance was set at $p < 0.05$.

Results

Baseline and Surgery Parameters

Table 1 summarizes the clinical, radiological, and demographic characteristics of the patients. A total of 93 patients underwent anterior cervical corpectomy. Sixty-one patients underwent anterior column reconstruction using iliac grafts, and 32 underwent reconstruction with expandable cages. Representative pre- and postoperative images from both groups are shown in Figures 1 and 2.

Clinical Efficacy Assessment

Preoperative and postoperative mJOA scores, local angulation, and C2-C7 Cobb angles are presented in Table 2. In both the iliac graft and cage groups, the change in mJOA scores from before to after surgery was significant ($p < 0.001$), whereas the improvement in PFR was not statistically significant ($p = 0.76$). Although the difference in PFR between the two groups was not statistically significant ($p = 0.76$), both the iliac graft and cage groups demonstrated significant improvement in mJOA scores after surgery ($p < 0.001$). However, no statistically significant difference in PFR was observed between the two groups ($p = 0.76$). Postoperative mJOA scores improved from 13.6 ± 2.1 to 15.8 ± 1.7 in the iliac graft group and from 13.2 ± 2.3 to 15.5 ± 1.9 in the cage group, indicating overall functional recovery. Preoperative and three-month postoperative mJOA scores and the changes in local angulation are presented in Table 2.

Table 1. Demographic parameters and pre- and postoperative surgical details in the iliac graft and cage groups

Variable	All patients \pm SD 93 (%)	Iliac graft \pm SD 61 (%)	Cage \pm SD 32 (%)	p value
Age \pm SD	54.3 \pm 10.2	53.7 \pm 10.2	55.3 \pm 10.1	0.48
Male	52 (55.9)	32 (52)	20 (62)	0.35
Female	41 (44.1)	29 (48)	12 (38)	
Corpectomy level				0.16
C4	10 (10.8)	5	5	
C5	21 (22.6)	12	9	
C6	28 (30.1)	22	6	
C7	1 (1.1)	0	1	
C3-4	1 (1.1)	0	1	
C4-5	6 (6.5)	5	1	
C5-6	25 (26.9)	17	8	
C6-7	1 (1.1)	0	1	
Duration of operation (hour) \pm SD	4.0 \pm 1.1	3.9 \pm 1.0	4.2 \pm 1.1	0.22
Duration of hospital stay (day) \pm SD	5.4 \pm 8.3	3.7 \pm 4.7	8.5 \pm 12.0	0.007
Duration of symptom	17.3 \pm 17.3	16.3 \pm 12.5	19.2 \pm 20.1	0.46
MRI signal properties				0.21
Normal T1/normal T2	31	20	11	
Normal T1/hyperintense T2	53	40	13	
Hyperintense T1/hyperintense T2	9	1	8	

Demographic characteristics and perioperative parameters of patients in the iliac graft and cage groups. Values are presented as mean \pm SD or number (percentage) unless otherwise specified. Statistical comparisons between groups were performed using the Student's t-test or Mann-Whitney U test for continuous variables and the chi-square test for categorical variables. SD: Standard deviation, MRI: Magnetic resonance imaging

Comparing Radiography of Patients with Iliac Grafts and Expandable Cages

In the iliac graft group, the mean Cobb angle improved from 3.17° preoperatively to 9.12° in the early postoperative period, indicating restoration of cervical lordosis ($p < 0.001$). The late postoperative Cobb angle was 3.86°, representing a statistically significant improvement compared with the preoperative value ($p = 0.02$). Similarly, in the expandable-cage group, the mean Cobb angle improved from 0.99° preoperatively to 5.83° postoperatively ($p = 0.025$). However, at three months postoperatively, the mean C2-C7 Cobb angle was 4.31° ($p = 0.33$).

In the iliac graft group, the mean early postoperative local angulation was 10.15° (range -4° to 25°), whereas the mean late postoperative local angulation was 5.9° (range -19° to 22°) ($p = 0.05$). In the cage group, the mean early postoperative local angulation was 8.04° (range -11° to 26°),

and the mean late postoperative angulation was 6.50° (range -9° to 24°) ($p = 0.24$).

Complications

Fourteen patients experienced surgery-related complications. In the iliac graft group, seven patients experienced complications, including one case of esophageal rupture, two malunions, one C5 palsy, one dural tear, and two graft displacements. In the cage group, seven patients experienced complications: two C5 palsies, two cases of cage malposition, one hematoma, one malunion, and one dural tear. Two patients underwent revision surgery because of screw malposition. Comparison of complication rates between the iliac graft and cage groups using the Mann-Whitney U test revealed no statistically significant difference ($p = 0.114$).

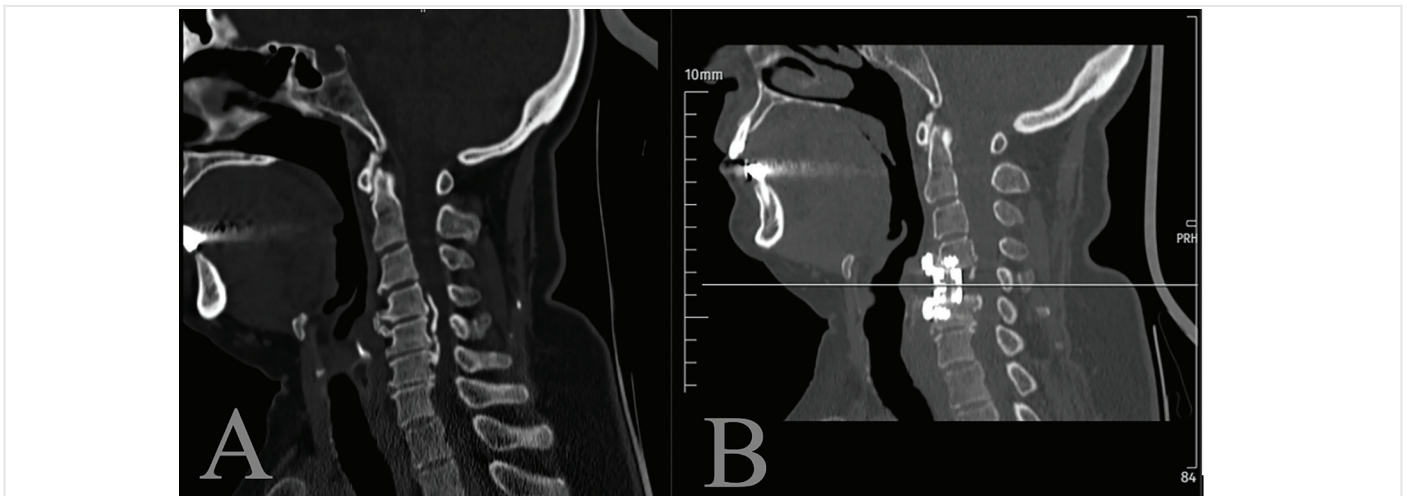


Figure 1. A 52-year-old male patient with C4-6 cervical spinal stenosis reconstructed with a titanium cage (preoperative mJOA score: 14). (A) Preoperative computed tomography (CT) scan showing destruction of the C4-6 posterior vertebral bodies and intervertebral discs, resulting in segmental instability. (B) Postoperative CT scan obtained 12 months after C4-6 corpectomy and titanium cage reconstruction demonstrates optimal cage positioning and satisfactory cervical stabilization (postoperative mJOA score: 17). mJOA: Modified Japanese Orthopaedic Association score

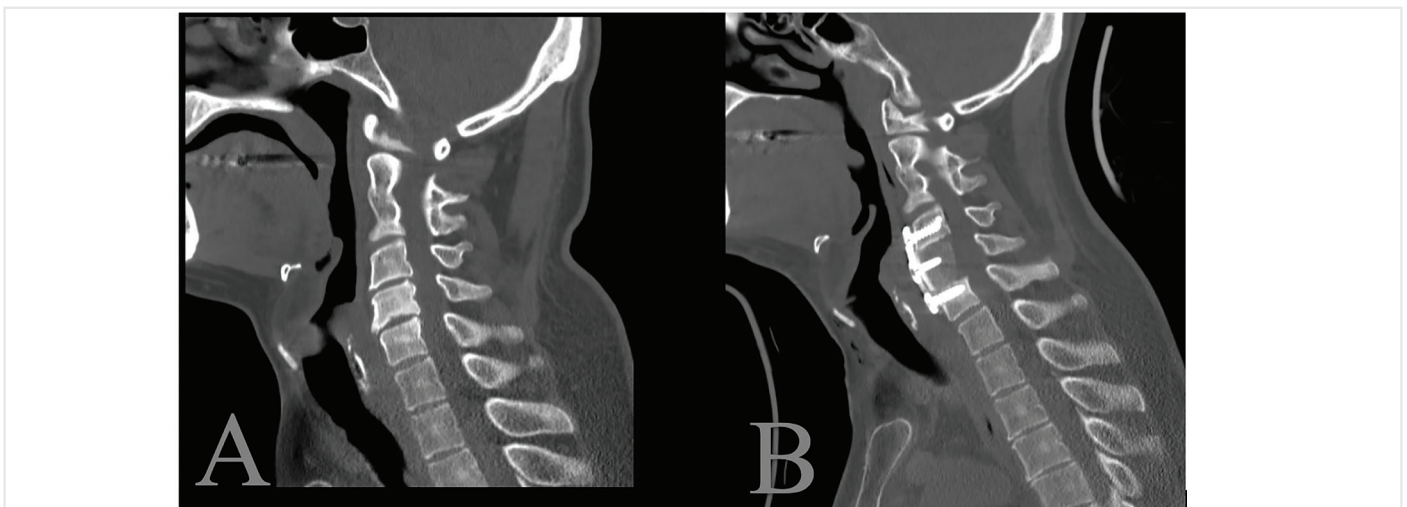


Figure 2. A 37-year-old male patient with C3-5 cervical spinal stenosis reconstructed using an autologous iliac graft (preoperative mJOA score: 13). (A) Preoperative computed tomography (CT) scan revealing multilevel stenosis between C3 and C5. (B) Postoperative CT scan obtained 12 months after C5 corpectomy and iliac graft reconstruction shows proper graft integration and stable cervical alignment (postoperative mJOA score: 18). mJOA: Modified Japanese Orthopaedic Association score

Table 2. Pre- and postoperative neurological and radiological findings in the iliac graft and cage groups

Variable	All patients \pm SD 93 (%)	Iliac graft \pm SD 61 (%)	Cage \pm SD 32 (%)	p value
Preoperative C2-C7 Cobb angle	2.42 \pm 9.59	3.17 \pm 9.71	0.9 \pm 9.33	0.06
Early postoperative C2-C7 Cobb angle	7.99 \pm 7.66	9.12 \pm 7.24	5.83 \pm 8.08	0.04
Late postoperative C2-C7 Cobb angle	4.14 \pm 8.34	3.86 \pm 7.01	4.31 \pm 9.01	0.80
Early postoperative local angulation	9.4 \pm 7.47	10.1 \pm 6.55	8.04 \pm 8.91	0.19
Late postoperative local angulation	6.1 \pm 7.63	5.91 \pm 7.58	6.53 \pm 7.85	0.70
Preoperative mJOA scores				0.04
Mild (mJOA >15)	55	35	20	
Moderate (mJOA 12-14)	29	23	6	
Severe (mJOA <12)	9	3	6	
Postoperative mJOA scores				0.13
Mild (mJOA >15)	79	55	24	
Moderate (mJOA 12-14)	6	3	3	
Severe (mJOA <12)	8	3	5	

Pre- and postoperative neurological and radiological findings in the iliac graft and cage groups Values are presented as mean \pm standard deviation or number (percentage) unless otherwise specified. C2-C7 Cobb angle and local angulation measurements were compared across time points to evaluate sagittal alignment correction and maintenance. SD: Standard deviation, mJOA: Modified Japanese Orthopaedic Association score, C2-C7: Cervical vertebrae 2 to 7

Discussion

Currently, the gold standard for anterior column reconstruction following corpectomy is the use of an autologous bone graft harvested from the iliac crest. Nevertheless, approximately 25% of patients undergoing this procedure have been reported to experience donor-site complications. The most common complications include postoperative donor-site pain, hematoma or seroma formation, bone fracture, infection, and blood loss (10). Consequently, many surgeons prefer to use titanium cages to avoid these donor-site morbidities. Numerous interbody fusion devices have been developed to overcome the limitations of bone grafts, enhance endplate-to-graft apposition, and provide immediate postoperative spinal stability. These devices are made from various materials, including titanium, titanium alloys (such as titanium–aluminium–vanadium alloys), and polyetheretherketone (11). Titanium remains the principal material due to its superior corrosion resistance, biocompatibility, and high strength-to-weight ratio. Titanium promotes osseointegration, a process in which the implant directly integrates with the surrounding bone. Moreover, the surface of titanium cages can be modified to enhance cell adhesion and promote osseointegration (12). Although titanium cages are widely used, there is limited and conflicting evidence directly comparing the clinical outcomes of patients treated with expandable cages versus those treated with iliac grafts (3). The aim of this study was to compare the risks and benefits of autogenous iliac crest bone grafts and titanium cages for anterior column reconstruction in patients with cervical spinal stenosis.

The Clinical Efficacy of Using Iliac Grafts vs. Expandable Cages

When comparing the clinical outcomes between the iliac graft and expandable-cage groups as measured by the preoperative mJOA scale and PFR rate, both groups demonstrated significant improvement in mJOA scores, whereas the difference in PFR between groups was not statistically significant. This finding suggests that iliac grafts may be used as effectively as titanium cages for anterior column reconstruction.

In clinical practice, given the costs of implant manufacturing and materials, reconstruction with autologous bone grafts remains the treatment of choice.

Cobb Angles of Cervical Curvature in Early and Late Postoperative Periods

A stable Cobb angle between the early and late postoperative periods indicates that the surgical technique provides durable correction, contributing to the long-term success of spinal fusion. Techniques demonstrating minimal regression of the Cobb angle over time indicate more robust stabilization, potentially reflecting improved bone integration, load distribution, or structural integrity (13). Analysis of the radiographic outcomes comparing iliac grafts with expandable cages showed evident postoperative improvements in cervical alignment, as measured by the Cobb angle, in both groups. Although both groups exhibited significant early postoperative improvements, a slight regression in Cobb angles was observed during the late postoperative period. In a previous comparative study of iliac grafts and titanium cages, both groups achieved solid bone fusion and all patients demonstrated marked improvement in neurological function, as reflected by increased mJOA scores (3). Tosun et al. (14) reported that expandable cages were more effective in preventing the loss of sagittal alignment. However, in a similar study, Debnath et al. (15) observed that the absence of kyphosis correction had no impact on overall neurological recovery. A minor loss of kyphotic correction or of intervertebral height is clinically acceptable.

Local Angulation and its Role on Surgical Outcomes

Local angulation plays a significant role in determining surgical outcomes, particularly in anterior cervical column reconstruction. When postoperative local angulations were compared between the iliac graft and expandable cage groups, both groups demonstrated improvement during the early postoperative period. However, over time, partial loss of local angulation correction was observed in both groups.

This regression appeared more pronounced in the expandable-cage group. A possible explanation for this regression is that cages, typically made of titanium or other durable materials, provide immediate structural support. However, minor positional shifts may occur during integration with the surrounding bone. In addition, their use can be technically challenging, particularly when modifying the cage size to fit the defect without compromising endplate integrity.

Complications and their Implications for Surgical Choices

Both techniques demonstrated similar complication rates, with seven complications reported in each group: in the iliac graft group, complications included one esophageal rupture, two malunions, one C5 palsy, one dural tear, and two graft displacements; in the cage group, complications included two C5 palsies, two cases of cage malposition, one hematoma, one malunion, and one dural tear. These complications pose distinct clinical risks. Malunion can impair spinal stability and healing, whereas C5 palsy may compromise upper limb function and require prolonged rehabilitation. Dural tears increase the risk of cerebrospinal fluid leakage, and displacement of the graft or cage may necessitate revision surgery. A limitation of this study is that postoperative pain at the surgical site was not assessed as a complication for the iliac graft group.

Revision Surgery: Indications and Outcomes

In anterior cervical corpectomy for cervical stenosis, the choice between iliac grafts and expandable cages may influence the likelihood of requiring revision surgery. In our study, only two patients in the cage group required revision surgery due to implant malposition. Both patients had prolonged recovery periods (hospital stays of 14 and 10 days, respectively), yet both demonstrated improvement in their mJOA scores, reaching 17 postoperatively. To minimize the need for revision surgery and prevent implant malposition, meticulous preoperative planning using advanced imaging, together with refined surgical techniques, is essential. These revision surgeries underscore the potential risks associated with inaccuracies in implant placement.

Study Limitations

The relatively small sample size constitutes one of the primary limitations of this study. This sample size may be insufficient to fully evaluate differences in early and late postoperative outcomes and complication rates. Additionally, because the study was retrospective, the unequal distribution of patients between the iliac graft (n=61) and cage (n=32) groups, along with the absence of a prior power analysis, may have reduced the statistical power for subgroup comparisons. Furthermore, selection bias could not be completely eliminated, as surgeon preference played a major role in determining the reconstruction method. Prospective, long-term studies with balanced group sizes are warranted to more accurately assess the comparative outcomes of iliac grafts and expandable cages.

Conclusion

In conclusion, both expandable cages and iliac grafts effectively improve postoperative mJOA scores following anterior column reconstruction.

Although expandable cages provide superior early correction of cervical kyphosis, iliac grafts offer more stable long-term alignment; therefore, the choice of reconstruction method should be individualized based on each patient's clinical and radiological characteristics. Although each technique carries distinct risks, their overall complication rates are comparable. Iliac grafts are more prone to displacement, whereas cage malposition may require revision surgery. For patients requiring immediate postoperative alignment correction, iliac grafts may represent a more favourable option; nevertheless, the approach selected should take into account the specific complication profile associated with each method.

Ethics

Ethics Committee Approval: The study was approved by the Tekirdağ Dr. İsmail Fehmi Cumalıoğlu City Hospital Clinical Research Ethics Committee (approval number: 99, date: 19.04.2024).

Informed Consent: The written informed consent was obtained from all participants.

Footnotes

Authorship Contributions: Surgical and Medical Practices - H.D.; Concept - H.D., N.Ş.; Design - N.Ş.; Data Collection or Processing - H.D., N.Ş.; Analysis or Interpretation - H.D.; Literature Search - H.D., N.Ş.; Writing - H.D., N.Ş.

Conflict of Interest: No conflict of interest was declared by the authors.

Financial Disclosure: The authors declared that this study received no financial support.

References

1. Bailey RW, Badgley CE. Stabilization of the cervical spine by anterior fusion. *J Bone Joint Surg Am.* 1960; 42: 565-94.
2. Cappelletto B, Giorgiutti F, Balsano M. Evaluation of the effectiveness of expandable cages for reconstruction of the anterior column of the spine. *J Orthop Surg (Hong Kong).* 2020; 28: 2309499019900472.
3. Shao MH, Zhang F, Yin J, Xu HC, Lyu FZ. Titanium cages versus autogenous iliac crest bone grafts in anterior cervical discectomy and fusion treatment of patients with cervical degenerative diseases: a systematic review and meta-analysis. *Curr Med Res Opin.* 2017; 33: 803-11.
4. Demontiero O, Vidal C, Duque G. Aging and bone loss: new insights for the clinician. *Ther Adv Musculoskelet Dis.* 2012; 4: 61-76.
5. Marbacher S, Hidalgo-Staub T, Kienzler J, Wüergler-Hauri C, Landolt H, Fandino J. Long-term outcome after adjacent two-level anterior cervical discectomy and fusion using stand-alone plasmaphore-covered titanium cages. *J Neurol Surg A Cent Eur Neurosurg.* 2015; 76: 199-204.
6. Chou YC, Chen DC, Hsieh WA, Chen WF, Yen PS, Harnod T, et al. Efficacy of anterior cervical fusion: comparison of titanium cages, polyetheretherketone (PEEK) cages and autogenous bone grafts. *J Clin Neurosci.* 2008; 15: 1240-5.
7. Jang JW, Lee JK, Lee JH, Hur H, Kim TW, Kim SH. Effect of posterior subsidence on cervical alignment after anterior cervical corpectomy and reconstruction using titanium mesh cages in degenerative cervical disease. *J Clin Neurosci.* 2014; 21: 1779-85.
8. Mastronardi L, Elsawaf A, Roperto R, Bozzao A, Caroli M, Ferrante M, et al. Prognostic relevance of the postoperative evolution of intramedullary spinal cord changes in signal intensity on magnetic resonance imaging after anterior

- decompression for cervical spondylotic myelopathy. *J Neurosurg Spine*. 2007; 7: 615-22.
9. Hirabayashi K, Miyakawa J, Satomi K, Maruyama T, Wakano K. Operative results and postoperative progression of ossification among patients with ossification of cervical posterior longitudinal ligament. *Spine (Phila Pa 1976)*. 1981; 6: 354-64.
 10. Boehm KS, Al-Taha M, Morzycki A, Samargandi OA, Al-Youha S, LeBlanc MR. Donor site morbidities of iliac crest bone graft in craniofacial surgery: a systematic review. *Ann Plast Surg*. 2019; 8: 352-8.
 11. Muthiah N, Yolcu YU, Alan N, Agarwal N, Hamilton DK, Ozpinar A. Evolution of polyetheretherketone (PEEK) and titanium interbody devices for spinal procedures: a comprehensive review of the literature. *Eur Spine J*. 2022; 31: 2547-56.
 12. Rao PJ, Pelletier MH, Walsh WR, Mobbs RJ. Spine interbody implants: material selection and modification, functionalization and bioactivation of surfaces to improve osseointegration. *Orthop Surg*. 2014; 6: 81-9.
 13. Cao Y, Xu C, Sun B, Cui C, Zhang K, Wu H, et al. Preoperative cervical Cobb angle is a risk factor for postoperative axial neck pain after anterior cervical discectomy and fusion with zero-profile interbody. *Orthop Surg*. 2022; 14: 3225-32.
 14. Tosun B, Erdemir C, Yonga O, Selek O. Surgical treatment of thoracolumbar tuberculosis: a retrospective analysis of autogenous grafting versus expandable cages. *Eur Spine J*. 2014; 23: 2299-306.
 15. Debnath UK, McConnell JR, Kumar S. Single-stage combined anterior corpectomy and posterior instrumented fusion in tuberculous spondylitis with varying degrees of neurological deficit. *Int J Spine Surg*. 2021;15:600-11.