

Variations in the course of the external branch of the superior laryngeal nerve and their importance in surgical procedures: an experimental cadaveric study

Authors' Contribution:
 A – Study Design
 B – Data Collection
 C – Statistical Analysis
 D – Data Interpretation
 E – Manuscript Preparation
 F – Literature Search
 G – Funds Collection

Gkionoul Nteli Chatzioglou^{1ACDEF}, Elif Sari^{2AC}, Özcan Gayretli^{3EF}, Osman Coşkun^{3B}, Adnan Öztürk^{1D}, İlke Ali Gürses^{4B}

¹Department of Anatomy, Istanbul Health and Technology University, Istanbul, Turkey

²Department of Ear Nose Throat, School of Medicine, Istanbul Aydın University, Istanbul, Turkey

³Department of Anatomy, Faculty of Medicine, Istanbul University, Istanbul, Turkey

⁴Department of Anatomy, Faculty of Medicine, Koc University, Istanbul, Turkey

Article history: Received: 02.12.2022 Accepted: 11.01.2023 Published: 14.01.2023

ABSTRACT:

Introduction: Injury of the external branch of the superior laryngeal nerve can cause a hoarse or weak voice due to the functional loss (dysergia) of the cricothyroid muscle. Defining the anatomical variations of the external branch of the superior laryngeal nerve and estimating their frequency are crucial for surgical interventions.

Aim: To reveal the topography of the external branch in the Anatolian population, to prevent injury of it during the surgical intervention in the anterior neck region.

Material and methods: 26 bilateral hemilarynges (4 females, 22 males) were dissected. The morphometric and morphological features of the external branch were examined. The obtained results were compared statistically, left and right.

Results: Landmarks such as the thyroid gland and laryngeal prominence were determined for the detection of the external branch. The variations of the course of the external branch and the points of piercing the cricothyroid muscle or inferior pharyngeal constrictor muscle were evaluated.

Discussion: Although safe approaches have been described for nerve protection during neck surgeries, injuries may occur during preliminary surgery as the mentioned nerve is thinner and more superficial than other branches of the vagus nerve. However, it can be detected more easily and safely by knowing the defined anatomical landmarks and morphological variations of the external branch.

Conclusion: The anatomical variations described can be a safe and important guide in surgeries of the anterior neck region.

KEYWORDS:

cadaver, safe surgical approach, superior laryngeal nerve, thyroidectomy, variation

ABBREVIATIONS

CT – cricothyroid muscle
 EbSLN – external branch of the superior laryngeal nerve
 ICP – inferior pharyngeal constrictor muscle
 LP – laryngeal prominence
 PP – piercing point
 RLN – recurrent laryngeal nerve
 SLN – superior laryngeal nerve
 ST – superior pole of the thyroid gland

INTRODUCTION

The muscles and mucosa of the larynx have important roles in some vital functions such as phonation, coughing, vomiting, and glottic reflexes [1–4]. All of these functions are achieved by the innervation

of the 10th cranial nerve and its branches [5]. Although the major efferent branch of the vagus nerve is the recurrent laryngeal nerve, the external branch of the superior laryngeal nerve is especially important as it is under surgical risk of injury during thyroid or carotid endarterectomy or can be damaged by post-operative inflammation, tethering, or scaring [6, 7]. Iatrogenic injury of the external branch of the superior laryngeal nerve (EbSLN) usually results in hoarseness, weak sound, and vocal fatigue due to the loss of efferent fibers to the cricothyroid muscle (CT) [8]. The frequency of EbSLN damage varies from 0% to 58% due to various surgical techniques used and different postoperative evaluations [9]. Additionally, the number of reliable anatomical landmarks within the region is limited [5, 10]. Therefore, this study aims to investigate the morphologic and morphometric features of EbSLN as well as its variations and identify the adjacent structures through landmarks in detail to prevent injuries and damage during surgery.

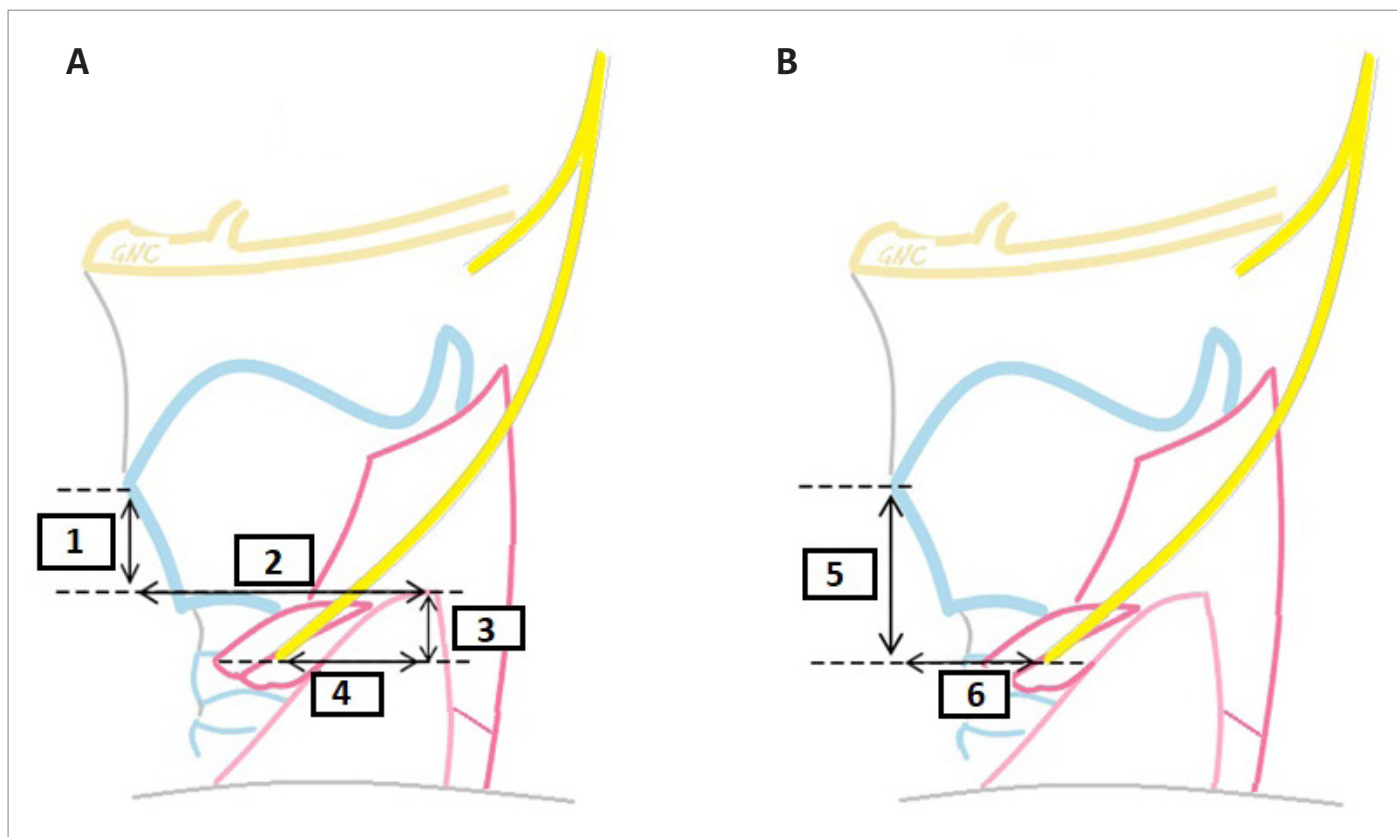


Fig. 1. The morphometric measured parameters. 1. the vertical distance between the superior pole of the thyroid gland and the laryngeal prominence, 2. the transverse distances between the superior pole of the thyroid gland and the laryngeal prominence, 3. the vertical distance between the superior pole of the thyroid gland and the point where the external branch of the superior laryngeal nerve pierces the cricothyroid muscle or the inferior constrictor pharyngeal muscle, 4. the transverse distance between the superior pole of the thyroid gland and the point where the external branch of the superior laryngeal nerve pierces the cricothyroid muscle or the inferior constrictor pharyngeal muscle (A). 5. the vertical distance between the laryngeal prominence and the point where the external branch of the superior laryngeal nerve pierces the cricothyroid muscle, 6. the transverse distances between the laryngeal prominence and the point where the external branch of the superior laryngeal nerve pierces the cricothyroid muscle (B).

MATERIALS AND METHODS

The current study was carried out on cadavers embalmed with a formaldehyde-ethanol-phenol-water solution at the xxxx University, Faculty of Medicine, Department of Following Institutional Ethics Committee approval (date: December 14th, 2018, number 1689). 26 larynges of 13 cadavers (2 female; 11 male) were dissected. This research was studied on adult cadavers.

Dissection techniques were applied as follows:

- First, a vertical incision from the gnathion to the jugular notch followed by a transverse incision from the jugular notch along the clavicle were performed. Then, the skin flap was raised and reflected laterally;
- Second, the superficial fascia, platysma, deep fascia, sternocleidomastoid, and strap muscles were dissected carefully in order to reach the visceral compartment. Within the compartment, the superior laryngeal nerve (SLN), external branch of SLN (EbSLN), superior pole of the thyroid gland (ST), superior thyroid artery and veins, and laryngeal prominence (LP) were revealed. Following the identification of SLN, EbSLN, and recurrent laryngeal nerve (RLN), en-bloc resections of the larynges were performed and further dissections were carried out.

The following parameters were measured:

- The transverse and vertical distances between ST and LP. The value of this distance was recorded as negative (–) when ST was above LP (Fig. 1A.);
- The transverse and vertical distances between ST and the point where EbSLN pierces the cricothyroid muscle or the inferior pharyngeal constrictor muscle (ICP) (Fig. 1A.). During the measurement of the vertical distance; in cases where ST was below the piercing point (PP) of EbSLN, the measurements were recorded as minus (–). In the same plane, the measurement was recorded as zero (0);
- The transverse and vertical distances between LP and the point where EbSLN pierces CT or ICP (Fig. 1B.). During the measurement of the vertical distance; in cases where LP was below PP, measured values were recorded as minus (–);
- The distance between EbSLN and ST was evaluated as below 1 cm and above 1 cm. In the study, all measurements were done with a digital caliper (MAJU 150 mm Digital Vernier, 2015, Malaysia). Data were analyzed using IBM SPSS Statistics for Windows, ver. 21.0. (SPSS, Armonk, NY, USA) ($\alpha = 0.05$). Differences in parameters between left and right sides were compared using t-tests. The datasets analyzed are available from the corresponding author on reasonable request.

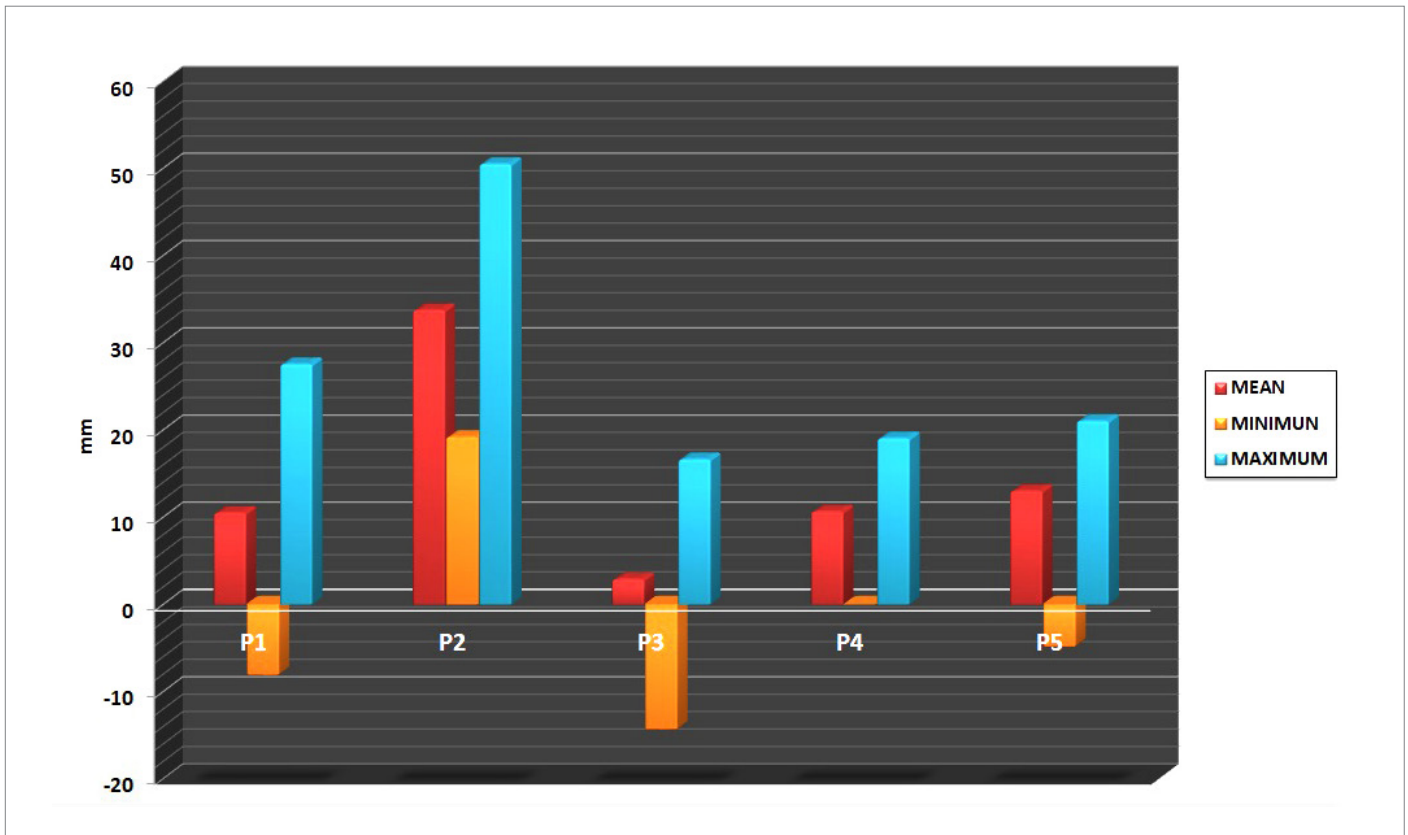


Fig. 2. The mean, standart deviation, minimum and maximum values of the measured parameters. P1: the vertical distance between the superior pole of the thyroid gland and the laryngeal prominence, P2: the transverse distances between the superior pole of the thyroid gland and the laryngeal prominence, P3: the vertical distance between the superior pole of the thyroid gland and the point where the external branch of the superior laryngeal nerve pierces the cricothyroid muscle or the inferior constrictor pharyngeal muscle, P4: the transverse distance between the superior pole of the thyroid gland and the point where the external branch of the superior laryngeal nerve pierces the cricothyroid muscle or the inferior constrictor pharyngeal muscle, P5: the vertical distance between the laryngeal prominence and the point where the external branch of the superior laryngeal nerve pierces the cricothyroid muscle, P6: the transverse distances between the laryngeal prominence and the point where the external branch of the superior laryngeal nerve pierces the cricothyroid muscle.

RESULTS

In the majority of the cases (92.3%), ST was located inferolaterally compared to LP. In 2 cases (7.69%), ST was approximately 7 mm above ST on the right side. The transverse distance between ST and LP (Fig. 2., P2) for the right and left sides was recorded to be 34.9 + 6.7 mm and 32.6 + 6.7 mm, respectively ($P = 0.028$). The vertical distance between ST and LP (Fig. 2., P1) was 8.5 + 8.5 mm and 12.5 + 6.9 mm for the right and left sides, respectively ($P = 0.049$).

Although EbSLN was found above ST in 22 cases, in 13 (50%) cases (5 left and 8 right), the piercing point of EbSLN was observed at less than 1 cm from ST and in 9 (34.61%) cases (6 left and 3 right) more than 1 cm. In only 2 (7.69%) cases (1 right, 1 left), it was recorded that EbSLN progressed medially to the thyroid gland and then passed just below and under the gland. Additionally, in 2 cases (7.69%), (1 right and 1 left) it was noted that the nerve branched out on the thyroid gland (Fig. 2.).

The piercing point (PP) of EbSLN according to the laryngeal prominence was located anterolaterally. The transverse distance between PP and LP (Fig. 2., P6) was measured as 22.68 + 8.37 mm on the left and 24.04 + 7.44 mm on the right ($P = 0.27$). The vertical distance between PP and LP (Fig. 2., P5) was 12.53 + 6.45 mm on the left and 13.51 + 4.26 mm on the right ($P = 0.48$) (Fig. 2.).

The values of both transverse and vertical distances were higher on the right. Only in one case (left side), the superficial course of EbSLN terminated above the laryngeal prominence by piercing the ICP muscle.

The average transverse distance between PP and ST (Fig. 2., P4) was 11.09 + 4.55 mm on the left and 10.23 + 5.11 mm on the right. The vertical distance between PP and ST (Fig. 2., P3) was 0.74 + 10.6 mm on the left and 5.06 + 8.58 mm on the right side. In 6 cases (all of them on the right side) the location of PP of EbSLN was above ST, in 19 cases below ST, and in one case PP was on the same plane with ST. The statistical correlation (left and right sides) of the transverse and vertical distance between PP and ST was $P = 0.28$ and $P = 0.09$, respectively.

In our study, the frequency of PP of EbSLN was classified into 5 different types (Fig. 3.). In Type I, which was the most common one, EbSLN ended by piercing ICP in 42.3%. In the second most common type (34.61%), EbSLN ended by reaching CT directly (Type IV). In Type III, EbSLN ended CT after piercing ICP (7.69%). The frequency of the remaining types (Type II and V) was recorded to be equal and the incidence of each was found to be 7.69% (Fig. 3.).

When the relationship of EbSLN with the thyroid pole was examined, the nerve was most commonly found above the thyroid

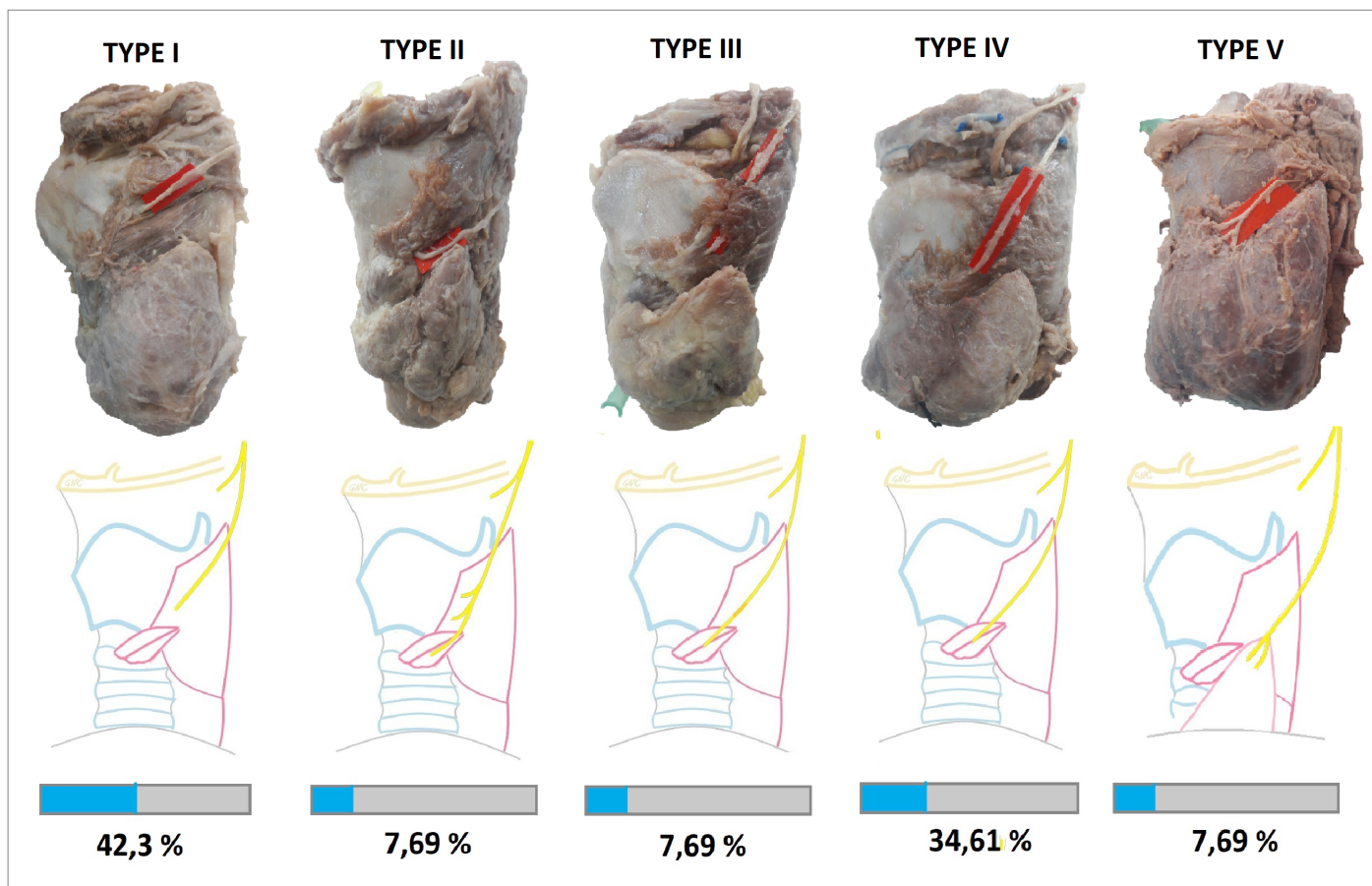


Fig. 3. The different types of piercing of the external branch of the superior laryngeal nerve the cricothyroid muscle, the inferior constrictor pharyngeal muscle and the thyroid gland. Pierce directly the inferior constrictor pharyngeal muscle (Type I). Ends by giving small branches to the inferior constrictor pharyngeal muscle and the cricothyroid muscle (Type II). Pierce the inferior constrictor pharyngeal muscle then reach the cricothyroid muscle (Type III). Without piercing the inferior constrictor pharyngeal muscle and pierce directly the cricothyroid muscle (Type I). Branching into the superior pole of the thyroid gland of the thyroid gland (Type V).

pole (Fig. 4A., 4B), while the nerve most rarely traveled above and behind the thyroid pole (Fig. 4C., 4D.).

DISCUSSION

Topography of External Branch of Superior Laryngeal Nerve

During surgeries of the neck region, and especially the larynx, it is substantial to detect the mentioned nerve in order to protect EbSLN and prevent its injury. The risk of injury is minimized in the case of detection of EbSLN, especially during thyroidectomy [11]. Since PP of EbSLN varies, its detection is difficult [12], and factors such as the anatomy and variations are of importance. In the literature, certain landmarks were described to detect this point more safely and the distances between them were measured. The EbSLN can terminate in CT or ICP muscles by piercing them after leaving the superior laryngeal nerve [12, 13]. In the present study, it was found that the nerve frequently pierced ICP (42.3%). In the study by Cha et al. [13], the rate of PP of EbSLN in ICP was found to be 51.7%, which seems to be close to our study. However, in our study, the piercing of EbSLN in CT was observed in 3 different ways: a) progressing the surface of the ICP muscle without piercing it – in 34.61%, terminating directly in the CT muscle (Friedman type 1), b) piercing ICP – in 7.69%, and then reaching

the CT muscle (Friedman 2 and 3), and c) finally it was noted that EbSLN terminated by giving small branches (7.69%) [14]. In only 2 cases (7.69%), EbSLN terminated by branching into the ST of the thyroid gland (Fig. 4D.). The classification of Friedman et al. [14] is related only to PP of EbSLN in the CT muscle but it ignores PPs in the thyroid gland and the relations with it. Although piercing of EbSLN (directly or not) in the CT muscle is frequent (50%), the frequency (42.3%) of ICP piercing is also common and significant. In thyroidectomy, the surgeons know that the mentioned nerve can be ended by giving small branches (7.69%), and that it is so crucial to preserve and identify it. To prevent the injuries of EbSLN during surgery, some approaches have been suggested. Since neck surgery without finding EbSLN increases the risk of injury, Friedman et al. [14, 15] reported that in this risky area a stimulator could be used for help. Another suggestion was made by Moosman et al. [16] who reported that a triangle (sternothyroid laryngeal triangle) or the Jolls space could be considered as a landmark for the detection of the nerve [11, 16]. Finally, many studies have claimed that it would be efficient to use superficial palpable structures as landmarks to detect that nerve [6, 8]. However, the first two recommendations have major disadvantages in the clinical field. Detection by stimulator to identify EbSLN is disputable because the intramuscular dissection needed to identify such nerves probably does more harm than good [17]. Moreover, using the triangle also may be difficult to

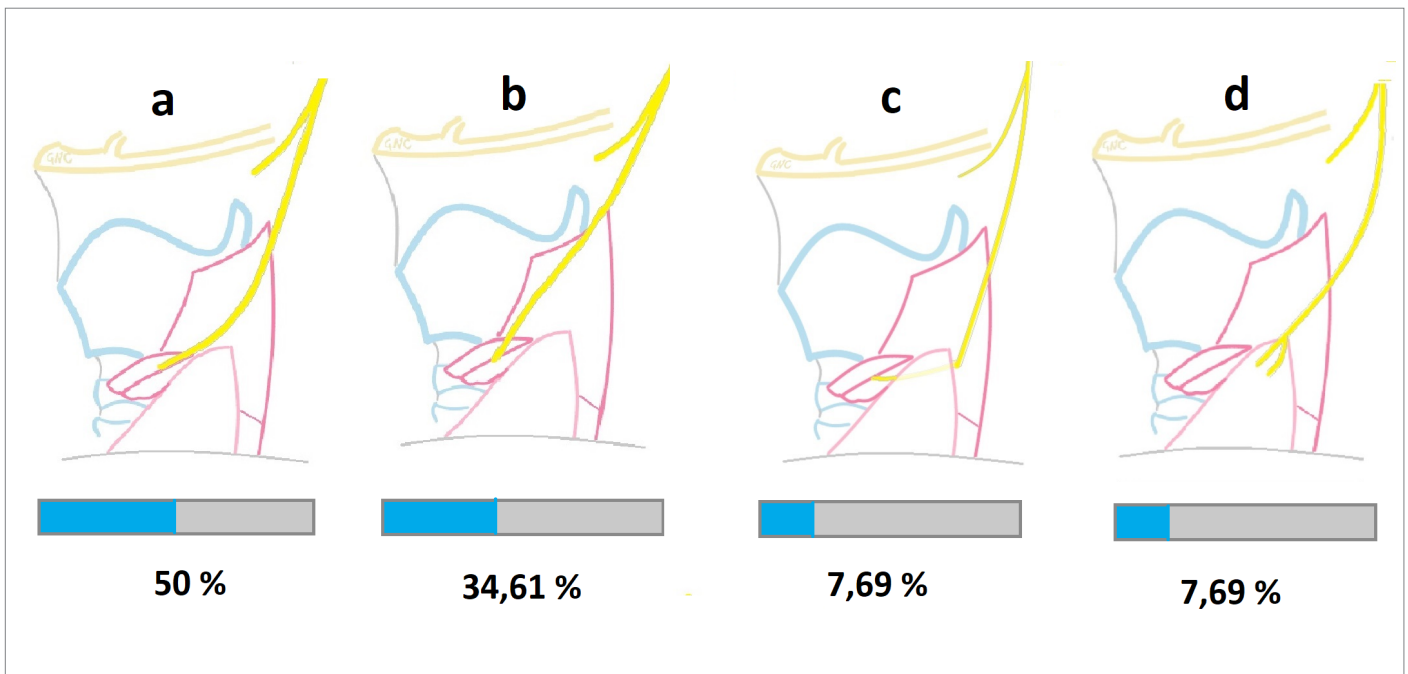


Fig. 4. The course and the ratios of the external branch of the superior laryngeal nerve according to the superior pole of the thyroid gland. (A) The external branch of the superior laryngeal nerve is located lesser than 1 cm of superior pole of the thyroid gland. (B) The external branch of the superior laryngeal nerve is located greater than 1 cm of superior pole of the thyroid gland. (C) The external branch of the superior laryngeal nerve is located under the thyroid gland. (D) The external branch of the superior laryngeal nerve branched out on the thyroid gland.

discover because there is no superficial or palpable landmark for the detection. In the current study, determined landmarks that are palpable can be used to show the location of EbSLN. Also, the results of these parameters can be used as a landmark in surgical approaches.

Relationship with the upper pole of the thyroid gland

In previous studies, ST was shown as one of the most important landmarks to prevent EbSLN injury, especially during thyroidectomy [18]. According to the study by Pagedar et al. [19], during thyroidectomy followed by removal of the thyroid it was observed that complications caused by EbSLN injury decreased [11]. Although EbSLN was detected in 98%, in the remaining 2% it could not be detected during routine thyroidectomy [19]. In order to prevent damage of EbSLN during thyroidectomy, the relation of the superior pole of the thyroid gland was examined in our study. Vertical and transverse distances between PP of EbSLN penetrating the muscles (CT and ICP) and ST were measured and evaluated (Fig. 3., 4.). During vertical distance measurements, the minus value was given when the piercing point was above ST. According to the results, the piercing point was seen above ST in 22 of 26 hemilarynges. The transverse distance from PP to ST was $11.09 + 4.55$ mm on the left, $10.23 + 5.11$ mm on the right, and the vertical distance on the left and on the right was $0.74 + 10.6$ mm and $5.06 + 8.58$ mm, respectively. The distance between the piercing point of EbSLN and ST was 0–1 cm, above 1 cm ($1>$), and below 1 cm ($1<$) in 13 (50%), 9 (34.61%), and 2 (7.69%) cases, respectively (Fig. 4.). In 2 cases (7.69%), EbSLNs overpassed ST (Fig. 4.). In previ-

ously reported studies, the distance (1 cm and above) between ST and PP of EbSLN was higher (46–62%) in Caucasians compared to other nationalities [19]. Not only ST but also vascular structures are used and reported in many studies as landmarks for detecting EbSLN [20]. However, the wide variation of vascular structures and their proximity to EbSLN put it at risk [21–23]. Especially in surgeries such as thyroidectomy, the possibility of injury increases with the artery being ligated [24].

The protrusion of the thyroid cartilage is the most easily palpable structure in the neck area in individuals [25]. That point, which is used as a landmark in surgical procedures (thyroidectomy, parathyroidectomy, thyroglossal cyst surgeries, etc.) allows for detection of EbSLN to prevent its injuries.

Variations are observed in the course of EbSLN. Since the nerve is thinner and more superficial than other branches of the vagus nerve, it is exposed to injuries in the preliminary stage of surgery. EbSLN can be discovered more easily and safely during surgical procedures by means of the anatomical landmarks and morphological variations determined in this study. Based on the statistical results obtained, they can also be used as a guide when approaching the right and left neck region.

DATA-SHARING STATEMENT

The data that support the findings of this study are available from the corresponding author upon reasonable request.

REFERENCES

1. Barczyński M., Konturek A., Stopa M., Honowska A., Nowak W.: Randomized controlled trial of visualization versus neuromonitoring of the external branch of the superior laryngeal nerve during thyroidectomy. *World J Surg*, 2012; 36(6): 1340–1347.
2. Stranding S.: *Gray's anatomy e-book: the anatomical basis of clinical practice*. Elsevier Sci, Amsterdam 2020.
3. Kambič V., Žargi M., Radšel Z.: Topographic anatomy of the external branch of the superior laryngeal nerve: its importance in head and neck surgery. *J Lar Otol*, 1984; 98(11): 1121–1124.
4. May R.E.: Voice changes after thyroidectomy: role of the external laryngeal nerve. *BMJ*, 1985; 290(6463): 243.
5. Kochilas X., Bibas A., Xenellis J., Anagnostopoulou S.: Surgical anatomy of the external branch of the superior laryngeal nerve and its clinical significance in head and neck surgery. *Clin Anat*, 2008; 21(2): 99–105.
6. Ng S.K., Li H.N., Chan J.Y.K., Wong E.W., Vlantis A.C.: A useful landmark to locate the external branch of the superior laryngeal nerve during thyroidectomy. *Gland Surg*, 2020; 9(3): 647.
7. Potenza A.S., Araujo Filho V.J., Cernea C.R.: Injury of the external branch of the superior laryngeal nerve in thyroid surgery. *Gland Surg*, 2017; 6(5): 552.
8. Bellantone R., Boscherini M., Lombardi C.P. et al.: Is the identification of the external branch of the superior laryngeal nerve mandatory in thyroid operation? Results of a prospective randomized study. *Surgery*, 2001; 130(6): 1055–1059.
9. Jansson S., Tisell L.E., Hagne I. et al.: Partial superior laryngeal nerve (SLN) lesions before and after thyroid surgery. *World J Surg*, 1988; 12(4): 522–526.
10. Morton R., Whitfield P., Al-Ali S.: Anatomical and surgical considerations of the external branch of the superior laryngeal nerve: a systematic review. *Clin Otolaryngol*, 2006; 31(5): 368–374.
11. Barczyński M., Freeman J.L., Cernea C.R.: External branch of superior laryngeal nerve (EBSLN) anatomic classification. In: *The Recurrent And Superior Laryngeal Nerves*, ed. G.W. Randolph. Springer Cham., New York 2016, 187–195.
12. Whitfield P., Morton R.P., Al-Ali S.: Surgical anatomy of the external branch of the superior laryngeal nerve. *ANZ Journal of Surgery*, 2010; 80(11): 813–816.
13. Cha Y.H., Moon S.Y., Jehoon O., Tansatit T., Yang H.M.: Anatomy of the external branch of the superior laryngeal nerve in Asian population. *Sci Rep*, 2017; 7(1): 1–9.
14. Friedman M., LoSavio P., Ibrahim H.: Superior laryngeal nerve identification and preservation in thyroidectomy. *AOHNS*, 2002; 128(3): 296–303.
15. Friedman M., Wilson M.N., Ibrahim H.: Superior laryngeal nerve identification and preservation in thyroidectomy. *Oper Tech Otolaryngol*, 2009; 20(2): 145–151.
16. Moosman D.A.: The external laryngeal nerve as related to thyroidectomy. *Surg. Gynecol Obstet*, 1968; 127: 1011–1016.
17. Lennquist S.: Thyroidectomy. In: *Textbook of Endocrine Surgery*, ed. O.H. Clark, Q.Y. Duh QY. WB Saunders, Philadelphia 1997 : 147–153.
18. Ortega C., Marañillo E., McHanwell S., Sañudo J., Vázquez-Osorio T.: External laryngeal nerve landmarks revisited. *Head & Neck*, 2018; 40(9): 1926–1933.
19. Pagedar N.A., Freeman J.L.: Identification of the external branch of the superior laryngeal nerve during thyroidectomy. *AOHNS*, 2009; 135(4): 360–362.
20. Tempel Z.J., Smith J.S., Shaffrey C. et al.: A multicenter review of superior laryngeal nerve injury following anterior cervical spine surgery. *Global Spine J*, 2017; 7(1): 7–11.
21. Dessie M.A.: Variations of the origin of superior thyroid artery and its relationship with the external branch of superior laryngeal nerve. *PLoS One*, 2018; 13(5): e0197075.
22. Kanté A., Ba B., Sidibé Y. et al.: External Branch of the Superior Laryngeal Nerve: Anatomy and Operating Hurts. *Int J Otorhinolaryngol*, 2018; 7(06): 388.
23. Kanté A., Sidibé Y., Ba B. et al.: Anatomical Dissection of the External Branch of the Superior Laryngeal Nerve to the Laboratory of Anatomy of the Faculty of Medicine of Bamako (Mali). *J Forensic Med.*, 2018; 6(4): 47–54.
24. Naraynsingh V., Cawich S., Hassranah D. et al.: Retrograde Thyroidectomy for preservation of the External Branch of the Superior Laryngeal Nerve: A case series. *Int. J. Surg. Case Rep.*, 2018; 53: 517–521.
25. Amabile A. H., Dekerlegand R. L., Muth S. et al.: Proximity of the Carotid Bifurcation to the Laryngeal Prominence: Results of a Cadaver Study and Recommendations for Safe Pulse Palpation. *J Geriatr Phys Ther*, 2020; 43(4): 53–57.

Table of content: <https://otolaryngologypl.com/issue/14978> Tables: – Figures: 4 References: 25

Copyright: Some right reserved: Polish Society of Otorhinolaryngologists Head and Neck Surgeons. Published by Index Copernicus Sp. z o.o.

Competing interests: The authors declare that they have no competing interests.



The content of the journal „Polish Society of Otorhinolaryngologists Head and Neck Surgeons” is circulated on the basis of the Open Access which means free and limitless access to scientific data.



This material is available under the Creative Commons – Attribution-NonCommercial 4.0 International (CC BY-NC 4.0). The full terms of this license are available on: <https://creativecommons.org/licenses/by-nc/4.0/legalcode>

Corresponding author: Gkionoul Nteli Chatzioglou (ORCID: 0000-0003-3728-6930) PhD; Department of Anatomy, Istanbul Health and Technology University, Istanbul, Turkey; Seyitnizam, Mevlana St. No: 85, 34015 Zeytinburnu, Istanbul, Turkey; E-mail: gonul.anatomy@gmail.com

Cite this article as: Chatzioglou G.N., Sari E., Gayretli O., Coskun O., Ozturk A., Gurses I.A.: Variations in the course of the external branch of the superior laryngeal nerve and their importance in surgical procedures: an experimental cadaveric study; *Otolaryngol Pol* 2023; 77 (2): 24-29; DOI: 10.5604/01.3001.0016.2167