

Morphological and Morphometric Variations of the Hyoid Bone in Anatolian Population

Gkionoul Nteli Chatzioglou¹ , Elif Toklu^{1,2} , Elif Bayraktar² , Ahmet Ertaş³ , Ayşin Kale² , Osman Coşkun² , Adnan Öztürk¹ , Özcan Gayretli² 

¹ Department of Anatomy, Faculty of Medicine, Istanbul Health and Technology University, Istanbul, Türkiye

² Department of Anatomy, Faculty of Medicine, Istanbul University, Istanbul, Türkiye

³ Department of Anatomy, Istanbul University, Cerrahpaşa Faculty of Medicine, Istanbul, Türkiye

Received: 2023-07-22 / Accepted: 2023-08-12 / Published Online: 2023-08-14

Correspondence

Gkionoul Nteli Chatzioglou, PhD

Address: Department of Anatomy,
Faculty of Medicine, Istanbul Health and
Technology University,

İmrahor St. No:82, 34015 Beyoglu,
Istanbul / Türkiye

E-mail: gkionoul.chatzioglou@istun.edu.tr

ABSTRACT

Objective: The morphological and morphometric variations of the hyoid bone (os hyoideum) are known to be significant in cervical surgeries and also serve as important evidence in forensic cases involving hanging and strangulation. The aim of this study is to investigate the morphological and morphometric differences of the hyoid bone.

Methods: Sixty-four adult hyoid bones of unknown age and gender were used in our study. Ethical approval for the study was obtained from the Istanbul Faculty of Medicine Clinical Research Ethics Committee (date/number: 15.12.2021/632888). The bone shape variations were classified into four main groups: D, U, B, and V types according to the morphometric measurements of the hyoid bone. Also the hyoid bones were evaluated based on their symmetry and isometry properties. Morphometric measurements were analyzed for reliability and repeatability using TEM, rTEM, and R tests, with the same person measuring twice. Measurements were calculated using the Image J program. The data were analyzed using SPSS v.21.

Results: The percentages of D, U, B, and V types were found to be 53.84%, 23.07%, 15.38%, and 11.53%, respectively. Among the hyoid bones, 34 (53.12%) were found to be asymmetrical, 30 (46.88%) symmetrical, 35 (54.69%) anisometric, and 29 (45.31%) were isometric.

Conclusion: Our study's results indicate that the hyoid bone of Anatolian individuals exhibits morphological differences compared to other populations. Understanding the morphological and morphometric values of the hyoid bone can contribute to clinical and forensic applications.

Keywords: forensic application, hyoid bone, morphometry, morphology, variation



This work is licensed under a Creative
Commons Attribution-NonCommercial 4.0
International License.

INTRODUCTION

The hyoid bone is a unique and intricate structure located in the neck, situated at the base of the skull and above the thyroid cartilage. Unlike other bones in the body, the hyoid bone does not articulate with any other bone, making it the only free-floating bone in the human skeleton. Its distinct shape and position play a crucial role in various physiological functions,

including speech, swallowing, and the stability of the neck. The hyoid bone is named from its resemblance to the Greek “ύψιλον (υ)» (upsilon), letter which is the 20th letter of the modern Greek alphabet. It is also called the lingual bone, because it supports the tongue and gives attachments to its numerous muscle. It is a bony arch, shaped like a horseshoe, and consisting of five segments, a body, two greater cornua,

and two lesser cornua. Moreover, morphologically, the hyoid bone resembles a horseshoe-shaped structure with a body and two pairs of projections known as horns. The body of the hyoid bone is centrally located and slightly curved, with a superior convexity and an inferior concavity. The superior surface of the body presents a midline ridge called the median sulcus, which serves as an attachment point for various muscles and ligaments. The horns of the hyoid bone project outwards and are named based on their anatomical positions. The greater horns, also known as the cornua, extend posteriorly and laterally from the body. They are relatively larger and serve as crucial points of attachment for muscles, including the muscles of the tongue and larynx. The smaller, more superior pair of projections is called the lesser horns, which are connected to the body via thin bony stalks [1-5].

The hyoid bone holds significant importance in the field of medicine due to its various functions and clinical implications. It plays a crucial role in swallowing, speech production, airway management, forensic medicine, surgical procedures, radiological imaging, and anthropological studies [6,7]. In terms of swallowing and speech, the hyoid bone acts as an anchor for the muscles involved in these processes, ensuring proper coordination and movement. Evaluating the position and function of the hyoid bone is essential in diagnosing and managing swallowing disorders (dysphagia) and speech impairments. For airway management, the hyoid bone's relationship with the upper airway and laryngeal structures is crucial. It contributes to maintaining a patent airway during respiration, making it important in procedures such as intubation, tracheostomy, and surgical interventions involving the airway [7-9]. In forensic medicine, the hyoid bone can provide valuable evidence in determining the cause and manner of death. Its examination for fractures or trauma helps forensic experts establish the presence of external pressure or force, especially in cases involving suspected strangulation or asphyxiation. It is involved in various

surgical procedures, particularly in head and neck surgery. Surgeries like hyoid suspension or hyoid advancement can address conditions like obstructive sleep apnea or improve airway stability [10-12]. Understanding the anatomy and biomechanics of the hyoid bone is crucial for the success and safety of these surgical interventions. Radiological imaging techniques, such as X-rays, Computed Tomography (CT) scans, and Magnetic Resonance Imaging (MRI), allow for detailed visualization and assessment of the hyoid bone. Radiological evaluation aids in diagnosing fractures, tumors, and other pathological conditions affecting the neck region. It plays a significant role in treatment planning and patient management [13]. In anthropological studies, the hyoid bone provides insights into human evolution, population genetics, and species identification [14]. Variations in its morphology among different populations or species contribute to our understanding of evolutionary patterns and help in identifying skeletal remains [15-18].

The aim of the study is to investigate the morphological and morphometric properties of the hyoid bone. By analyzing its shape, size, and structural characteristics, the study aims to contribute to our understanding of its variations and potential clinical implications. This research can further enhance our knowledge of the hyoid bone's role in medicine and potentially lead to advancements in diagnosing and managing conditions related to its function and structure.

MATERIALS AND METHODS

The hyoid bone of 64 adult cadavers from the Department of Anatomy, Istanbul Medical Faculty was included in our study. Ethical approval for the study was obtained from the Istanbul Faculty of Medicine Clinical Research Ethics Committee (Date: 2021.12.15, Approval Number:632888). The morphometric measurements of the parameters in our study were made from the anterior lateral and superior aspects of the hyoid bone.

The following parameters were measured from the anterior aspect of the hyoid bone:

Main Points;

- Examination of the morphology of the hyoid bone according to morphometric measurements.
- Identification and demonstration of variations of the hyoid bone.
- Precision assessment of hyoid bone measurements.
- The central height of the body of the hyoid bone (Figure 1A)
- The maximum height of the body of the hyoid bone (Figure 1A)
- The width of the body (corpus) of the hyoid bone (Figure 1B)

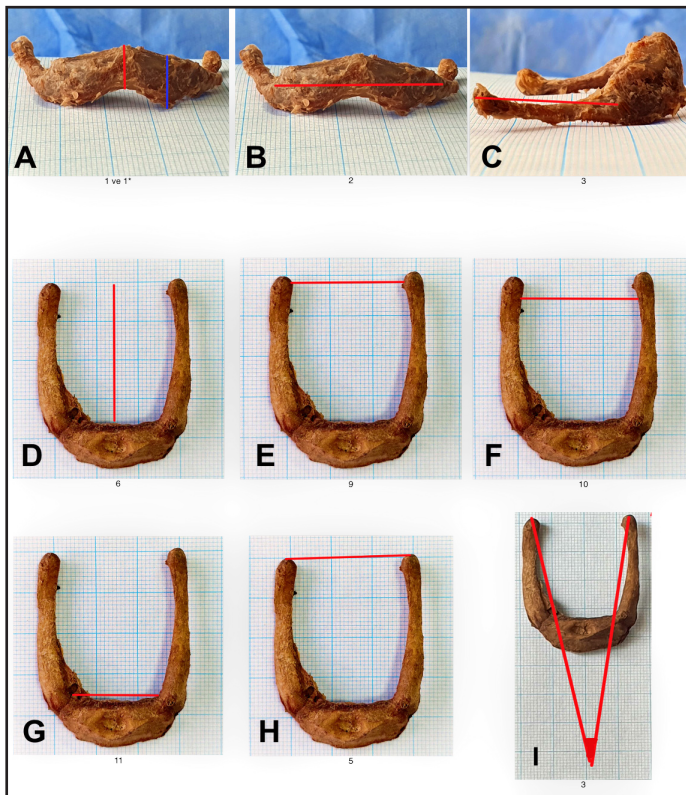


Figure 1. The morphometric measurements of hyoid bone from anterior (A, B and C) and superior (D, E, F, G, H and I) aspects. A. The central height of the body of hyoid bone (red vertical line), corpus max yükseklik (blue vertical line) and the maximum height of the body of hyoid bone B. The width of the body of hyoid bone. C. The length of the greater horn of the hyoid bone D. The anteroposterior vertical length of the hyoid bone: the distance between the inner-central side of the body of hyoid bone and the distal ends of the greater horns E. The transverse distance between the tubercles of greater cornua F. The major transverse axis G. The length of the body of hyoid bone H. The transverse distance between the posterior ends of greater horns I. The angle between the left and right greater horns

The following parameters were measured from the lateral aspect of the hyoid bone:

- The length of the greater horn of the hyoid bone (Figure 1C)
- The lateral angle of the greater horn-angulation I (if there is): the angle between the axis of greater horn and the hyoid body plane. In cases where the greater horn was in equal plan with the body of the hyoid bone, no angle measurement was performed (Figure 2A)
- The lateral angle of the greater horn-angulation II (if there is): when the posterior end of the greater horn is in the same plane as the body of the hyoid bone and in contact with the ground, and the angle formed by the section of the greater

horn between these two points without contact with the ground (Figure 2B and Figure 3).

The following parameters were measured from the superior aspect of the hyoid bone:

- The anteroposterior vertical length of the hyoid bone: the distance between the inner-central side of the body of hyoid bone and the distal ends of the greater horns. (Figure 1D)
- The transverse distance between the tubercles of greater cornua (Figure 1E)
- The major transverse axis (Figure 1F). The hyoid bones were also assessed based on their symmetry of the major transverse axis. If the midpoint of all transverse diameters was equidistant from the sagittal “y” axis, the bones were labelled as symmetrical; otherwise, they were categorized as asymmetrical according to Papadopoulos et al. [19] (Figure 4)
- The length of the body of the hyoid bone: the length was measured from the inner side of the hyoid bone (Figure 1G)
- The transverse distance between the posterior ends of greater horns (Figure 1H)
- The angle between the left and right greater horns: the angle formed by connecting the midpoints of the anterior and posterior ends of the greater horn (Figure 1I)

Morphometric measurements were performed twice by the same person. The Image J software (Rasband, W.S., ImageJ, U. S. National Institutes of Health, Bethesda, Maryland, USA, <https://imagej.nih.gov/ij/>, 1997–2016) was used to measure the morphometric parameters (Figure 3). The measurements’ reliability was assessed using TEM, rTEM, and R methods. The Technical Error of Measurement (TEM) quantifies the error magnitude, similar to the standard deviation, but it considers both measurement values. On the other hand, the Relative Technical Error of Measurement (rTEM) expresses the error size relative to the measurement size and is represented as a percentage. Lastly, the Coefficient of Reliability (R) is a reliability coefficient that reflects the proportional variation within an individual, independent of measurement error. Its value ranges from 0 (not reliable) to 1 (completely reliable).

The morphological features of the hyoid bones were classified into four main groups (Figure 5) as “D (deviating), H (horseshoe shape)/U (upsilon shape), B (boat shape) and V (triangular or resembling the V letter) types” according to the findings of the morphometric measurements. The hyoid bones’ shapes

were observed and categorized using the system proposed by Papadopoulos et al. According to this system, the bones are classified as follows:

- If the anterior part of the bone forms a half circle and its diameter is approximately the same as the posterior transverse diameter, it is referred to as the “U-Type” (Figure 5A).
- The “B-Type” resembles the transverse section of a boat, with its diameter coinciding with the major transverse axis (Figure 5B).
- If the anterior part is a half circle and one or both greater horns deviate to one or the other side at the posterior end, it is

classified as the “deviating-D-Type.” (Fig 5C)

- If the bone has a triangular shape or resembles the letter V, it falls under the “V-Type.” (Figure 5D).

Anisometric hyoid bone (if there is): a bone is considered isometric when the tips of both greater horns align on the same x-axis of the scale, regardless of whether the lengths of the horns are the same. On the other hand, if the tips of the greater horns do not align on the same x-axis and the transverse line from the tip of the shorter horn crosses the contralateral longer horn, the bone is considered an isometric (Figure 6).




Figure 2. The measurements of hyoid bone from the lateral aspect. A. Lateral angle of the right greater horn of hyoid bone-angulation I. B. Lateral anomalous angle of the right greater horn of hyoid bone-angulation II.

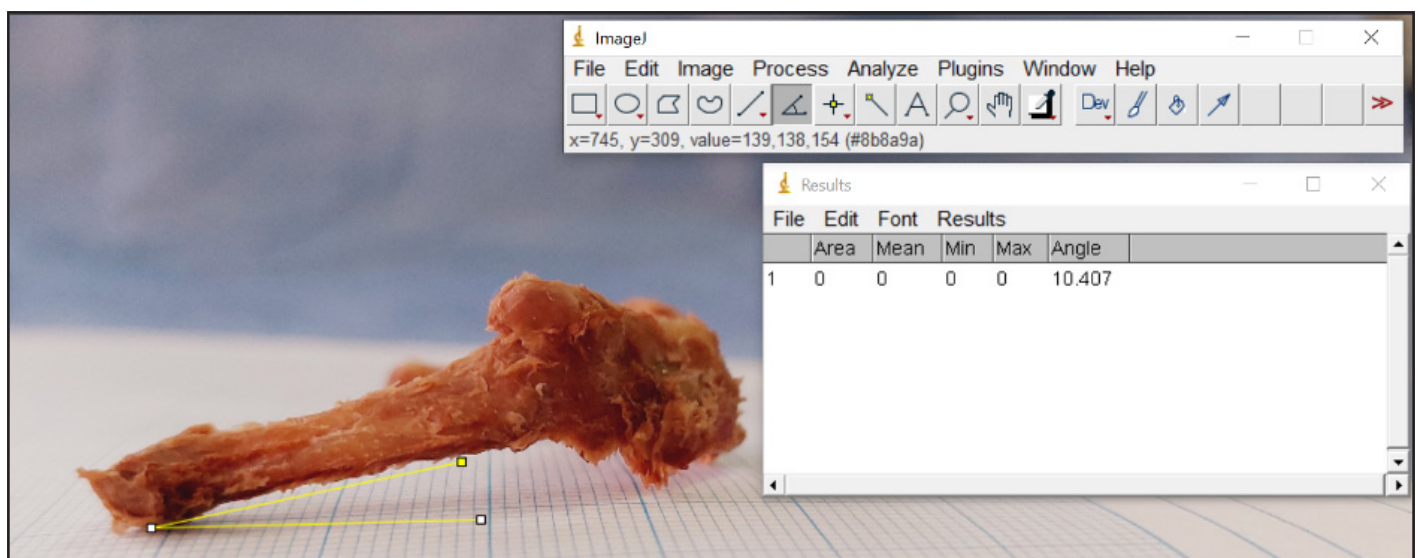


Figure 3. Measurement of right lateral angle of greater horn (angulation II) with Image J method

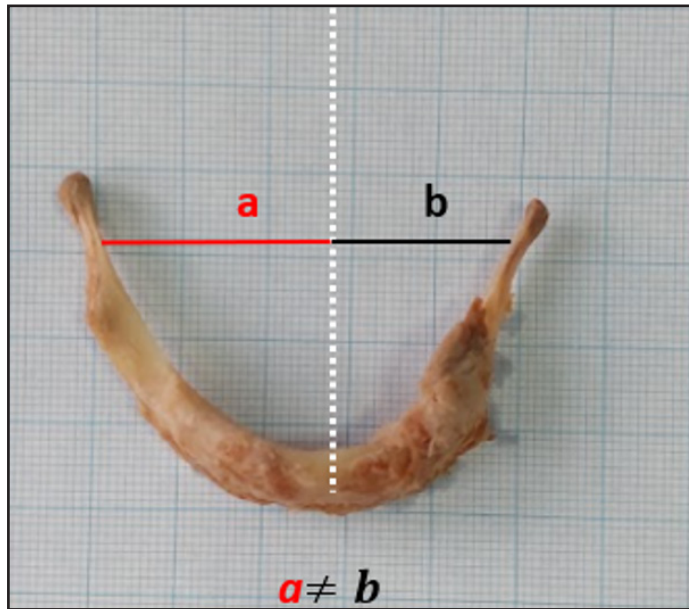


Figure 4. Asymmetric hyoid bone. The midpoint of the transverse diameters (red (a) and the black (b) lines) is not equidistant from the sagittal “y” axis (represented by the white dashed line).

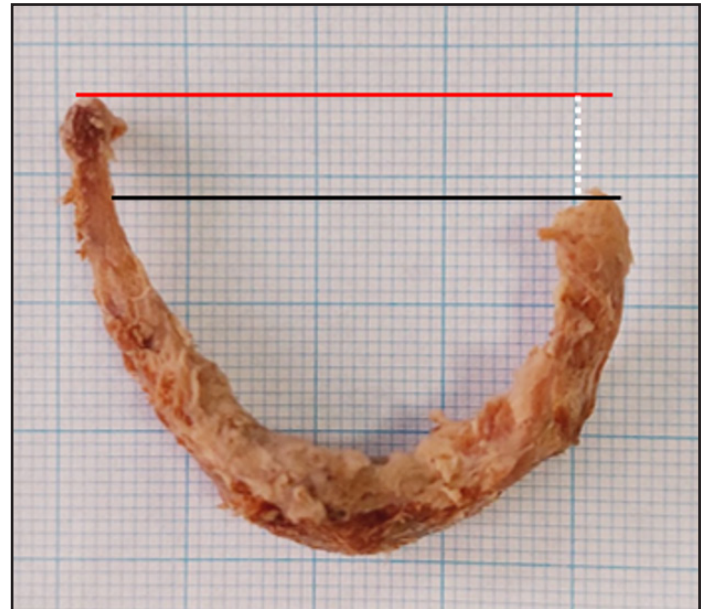


Figure 6. Anisometric hyoid bone. The tips of the greater horns do not align on the same x-axis and the transverse line from the tip of the shorter horn crosses the contralateral longer horn. The abnormal interval (white dashed line) between the posterior end of the right greater horn (red line) and the posterior end of the left posterior horn (black line).

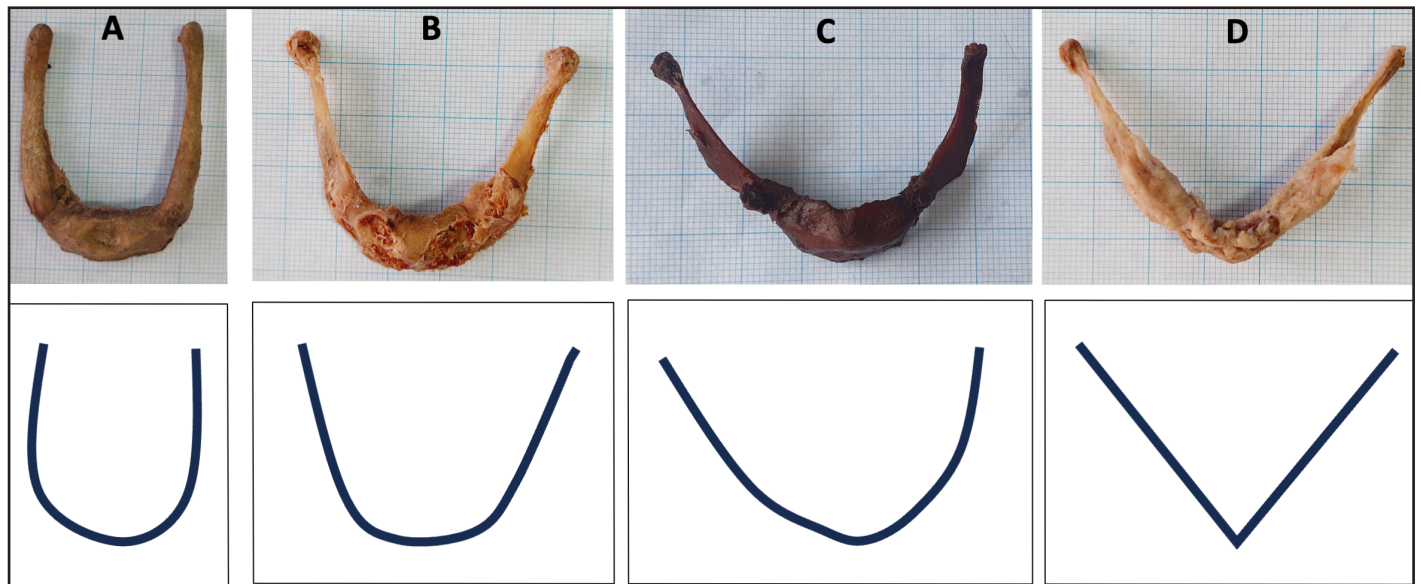


Figure 5. Morphometric measurements of the hyoid bone from the superior aspect for its morphological classification. A- U-type of hyoid bone B. B-type of hyoid bone C. D-type of hyoid bone D. V-type of hyoid bone

RESULTS

The morphological types of the hyoid bone were identified, including the D-type 33 hyoid bones (51.56%), H/U-type 15 hyoid bones (23.43%), B-type 9 hyoid bones (14.06%), and V-type 7 hyoid bones (10.93%) based on the Papadopoulos et al.

[19] classification (Figure 5). Apart from the main classification, 34 (53.12%) of the hyoid bones were asymmetric, 30 (46.88%) symmetric; 35 (54.69%) anisometric, 29 (45.31%) isometric. Regarding the morphometric measurements of the hyoid bone, the body of the morphometric features of hyoid bone and the

greater horns of the hyoid bone were measured. The angles between these structures were also included in our study. Additionally, we investigated the variability of the angle of the greater horns, which led to the identification of two distinct tendencies of angulation (Figure 2). These were classified as angulation I and angulation II, with proportions of 30/128 and 59/128, respectively. This intriguing discovery highlights the

diverse anatomical characteristics within the greater horn of the hyoid bone, providing valuable insights into its morphological variations. The results of our study related to the morphometric measurements are comprehensively presented in Table 1. Furthermore, morphometric measurements were controlled by TEM, rTEM and R tests in our study (Table 2).

Table 1. The mean morphometric measurements of the hyoid bone

Parameters	n	Mean±SD	Minimum-Maximum	View of hyoid bone
The central height of the body of hyoid bone	64*	10.98±1.08 mm	7.67-16.00 mm	Anterior aspect
The width of the body of hyoid bone	64*	23.54±3.52 mm	16.47-30.84 mm	Anterior aspect
The maximum height of the body of hyoid bone	64*	12.55±1.38 mm	9.18-17.42 mm	Anterior aspect
The transverse distance between the posterior ends of greater horns	64*	43.89±8.15 mm	28.80-62.09 mm	Superior aspect
The anteroposterior vertical length of the hyoid bone	64*	28.9±4.05 mm	20.14-41.78 mm	Superior aspect
The angle between the left and right greater horns	64*	40±7.60°	11.32-60.22°	Superior aspect
The transverse distance between the tubercles of greater cornua	64*	38.60±7.66 mm	25.02-55.96 mm	Superior aspect
The major transverse axis	64*	38.48±6.04 mm	26.06-53.31 mm	Superior aspect
The length of the body of hyoid bone	64*	19.15±3.31 mm	12.60-25.85 mm	Superior aspect
The length of the greater horn of the hyoid bone	128**	30.27±6.63 mm	22.92-48.31 mm	Lateral aspect
The lateral angle of the greater horn- angulation I	59/128**	7.52±7.73°	1.63-15.80°	Lateral aspect
The lateral angle of the greater horn-angulation II	30/128**	13.09±3.89 °	1.91-32.72°	Lateral aspect

SD: standard deviation, **n:** number of samples * number of hyoid bones, ** number of sides of hyoid bone

Table 2. Precision assessment of hyoid bone measurements

Parameters	n	TEM (mm)	rTEM (%)	R
The central height of the body of hyoid bone	26*	2.75	23.44	0.11
The width of the body of hyoid bone	26*	3.36	14.14	0.48
The maximum height of the body of hyoid bone	26*	2.70	24.11	0.15
The transverse distance between the posterior ends of greater horns	26*	0.43	0.97	0.99
The anteroposterior vertical length of the hyoid bone	26*	0.33	1.11	0.99
The angle between the left and right greater horns	26*	0.46	1.09	0.99
The transverse distance between the tubercles of greater cornua	26*	0.48	1.23	0.99
The major transverse axis	26*	0.34	0.88	0.99
The length of the body of hyoid bone	26*	0.36	1.85	0.97
The length of the greater horn of the hyoid bone	52**	1.08	3.52	0.97
The lateral angle of the greater horn- angulation I	21/52**	0.0096	0.12	0.99
The lateral angle of the greater horn-angulation II	12/52**	0.065	0.82	0.99

TEM: Technical error of measurement, **rTEM:** relative technical error of measurement, **R:** coefficient of reliability, **n:** number of samples, * number of hyoid bones, ** number of sides of hyoid bone

DISCUSSION

The Morphology of Hyoid Bone

The hyoid bone, located in the neck, exhibits various morphological variations that can be classified into distinct types. These classifications provide insights into the diversity of shape and structure observed in the hyoid bone across individuals and species. Studying the variations of hyoid bone is valuable in fields such as anatomy, anthropology, and forensic medicine, contributing to our understanding of evolutionary patterns, species identification, and investigations related to the neck and throat structures. The literature provides valuable insights into various hyoid shapes: H/U, V, B, and D, which were observed in the ranges of 39-55%, 5-48%, 26-48%, and 7-29%, respectively. In a groundbreaking study conducted by Koebke and Saternus in 1979 [20], they meticulously examined a total of 504 hyoid bones, presenting significant findings in the form of shape percentages. The results for H/U, V, B, and D were found as 48.1%, 40.9%, 40.9%, and 11.1%, respectively. This study has since provided valuable insights into the anatomical characteristics of hyoid bones and their respective shape distributions. Comparing our study's findings, we noted a similar occurrence of H/U hyoid shape (20.07%) to that reported by Papadopoulos et al. (38.5%) [19]. Likewise, the frequency of V-shaped hyoid bones in our investigation (11.53%) aligned closely with the findings of Martinez et al. (11.8%) [21], while the proportions of B (15.38%) and D (53.84%) shapes were comparable to those observed by Papadopoulos et al. 26.3% and 28.9%, respectively [19]. As we assessed the hyoid bones based on their symmetric and isometric properties, the symmetric frequency ranged from 52.6% to 93.1%, whereas the isometric frequency was found to be 41%. Generally, other studies [20, 22-24] reported a significantly higher incidence of symmetric hyoid bones, with the exception of Papadopoulos et al.'s findings [19]. Our study revealed a symmetric rate of 34.61%, which closely mirrored Papadopoulos et al.'s results [19]. In regard to the isometric properties, we found a congruence between our study's outcomes and the sole relevant study conducted by Papadopoulos et al. [19].

The Morphometry of Hyoid Bone

In our study, we examined the morphometric characteristics of the height and width parameters of the body of hyoid bones. We observed that our measurements bear the closest resemblance to the findings presented by Kinschuh et al. [18]. In various independent studies, researchers have focused on measuring the major transverse axis distance of the hyoid bone [15, 18, 24]

while some other studies taking into consideration the transverse distance between the upper points of the greater horns [15, 22, 25, 26] and the tubercle of the greater horns. In our research, we meticulously measured and recorded all three of these parameters, obtaining mean values of 38.7 mm, 44.19 mm, and 38.81 mm, respectively. Remarkably, our measurements closely resembled the findings reported by Kopuz et al. [24], indicating a notable similarity between the two studies. Regarding the parameter of the anteroposterior vertical length of the hyoid bone, we obtained a mean value of 29.39 mm in our study. This finding is consistent with a study conducted by Kim et al. [15] in 2006 in Korea, indicating a close resemblance between the two investigations. However, our mean value is lower than the one reported by Harjeeth et al. [27] in 1996. Conversely, it is significantly higher than the mean value reported in the study conducted by Kopuz et al. [24] in 2016. The mean value for the length of the body of hyoid bone is recorded as 19.63 mm in our study. This measurement was in close agreement with findings from studies conducted by Miller et al. [26] in the United States in 1998, Martinez et al. [21] in 2008 and Kindschuh et al. [18] in Africa in 2012. However, it was noted to be significantly lower compared to the mean values reported in studies conducted by Kopuz and Ortug [22], Leksan et al. [24] and Harjeet [27]. The angle between the left and right greater horns, as assessed from the superior aspect of the hyoid bone, has garnered attention in studies by Leksan et al. [22] and Kim et al. [15]. In our study, we measured this angle as $40^{\circ} \pm 2.62^{\circ}$ in accordance with the measurements reported by Kim et al. [15] and Dursun et al. [28]. However, Leksan et al. [22] have recorded a significantly lower value. Moreover, our study made a notable contribution by introducing new angles associated with the hyoid bone, termed the lateral angle of the greater horn-angulation I and angulation II, which had not been previously explored in the literature. The angulation I and II were measured as $7.52^{\circ} \pm 7.73^{\circ}$ and 13.09 ± 3.89 , respectively, providing novel insights into hyoid bone morphology. Notably, a remarkable finding was the presence of the lateral angulation (angulation I), which was observed in a total of 59 hyoid bones. Interestingly, there was no prior information available in the literature regarding this angle. However, we came across a case report published by Radunovic et al. [29], in 2018 that presented an angle of 33° between the right greater cornua axis and the hyoid body plane, whereas the left greater horn was found to be in alignment with the hyoid body plane. These unique observations added significant value to our understanding of hyoid bone morphology. The published case report by Radunovic et al. [29] describes a rare anatomical

asymmetry involving the greater horn of the hyoid bone and the superior thyroid horn. The variation could have significant functional implications, potentially affecting swallowing, speech articulation, and respiratory functions. The greater cornua's asymmetry may disrupt the biomechanics of surrounding neck structures, impacting muscle coordination during essential functions. Similarly, asymmetry in the superior thyroid horn may influence the larynx's movement and positioning, potentially affecting voice production and airway protection. Healthcare professionals need to be aware of such variations to consider their functional impact when evaluating and managing patients with speech, swallowing, or respiratory issues. Further research is necessary to fully comprehend the functional significance of this variation. Overall, reporting and documenting such cases contribute to our understanding of human anatomy and guide personalized patient care.

Additionally, our investigation involved a thorough examination of the hyoid bones from the superior aspect, revealing a notable observation. We observed that the endpoints of the greater horns in the bone were not aligned within the same plane. In light of this finding, we measured and recorded the anisometric angle formed between these two horns, quantified at $3.64^\circ \pm 1.3^\circ$. This novel insight shed light on the unique anatomical variation within the hyoid bone structure. Remarkably, Papadopoulos et al.'s [19] study was the only one to report on this aspect, revealing that 38 (59%) hyoid bones were classified as an isometric. This finding underscored the importance of understanding the diverse morphological characteristics within the hyoid bone, providing valuable insights for future research in this field.

The study on hyoid bone morphology and morphometric characteristics provides valuable insights, but it has limitations. These include a relatively small sample size, an observational design limiting causal inferences, and a lack of longitudinal data. Selection bias and measurement errors are also possible. It does not extensively explore clinical implications or differences between sexes and age groups. Additionally, a single-center study may introduce institutional-specific factors. Addressing these limitations in future research will enhance the understanding of hyoid bone morphology.

In conclusion, the study focused on examining the morphology and morphometric characteristics of the hyoid bone. Various morphological variations were identified, including U-shaped, boat shape, deviated shape and V-shaped configurations,

providing insights into the diversity of the bone across individuals and species. The morphometric analysis measured height and width parameters, aligning closely with previous research and revealing new angles associated with the hyoid bone. A rare anatomical asymmetry involving the greater horn and superior thyroid horn was observed, potentially impacting vital functions. The study highlighted the importance of understanding anatomical variations and their functional implications for personalized patient care. Overall, the research contributes valuable data to the understanding of hyoid bone diversity and complexity in the fields of anatomy, anthropology, and forensic medicine.

Limitations

In previous studies, especially in studies involving dry bones, the demographic information of the cadavers or bones used is not known [30]. Similarly, one of the most important limitations of our study is that more detailed statistical evaluations cannot be made due to the fact that the age and gender of the hyoid bones studied are not known.

Acknowledgment: The writing of this article was performed entirely by the authors and paraphrase was supported by ChatGPT-3.5, an artificial intelligence (AI) application. In the final stage, the version of the article sent to the journal was read and approved by all authors and it was accepted that all responsibilities related to the article belong to all authors.

Conflict of Interest: There is no conflict of interest between the authors.

Funding: This study had no financial support.

Ethics Committee Approval: Ethics committee approval was obtained from Istanbul Faculty of Medicine Clinical Research Ethics Committee (Approval date:15.12.2021, approval number: 632888).

Author Contributions: Conception: GNC; Design: GNC; Supervision: ÖG; Materials: ET, EB, AK, OC; Data Collection and/or Processing: GNC, ET, EB; Analysis and/or Interpretation: AE, AK, OC, ÖG; Literature Review: GNC, ÖG; Writing: GNC, AE, AK, OC, AÖ, ÖG; Critical Review: GNC, AK, OC, AÖ, ÖG.

REFERENCES

- [1] Standring S. *Gray's Anatomy: The Anatomical Basis of Clinical Practice*: Elsevier Limited; 2016.
- [2] Moore KL, Dalley AF, Agur AM. *Clinically oriented anatomy*: Lippincott Williams & Wilkins; 2013.
- [3] Gupta A, Kohli A, Aggarwal NK, Banerjee KK (2008) Study of age of fusion of hyoid bone. *Leg Med.* 10(5):253-256. <https://doi.org/10.22535/ofaj.89.83>
- [4] Sittel C, Brochhagen HG, Eckel HE, Michel O (1998) Hyoid bone malformation confirmed by 3-dimensional computed tomography. *Arch Otolaryngol-Head Neck Sur.* 124(7):799-801. <https://doi.org/10.1001/archotol.124.7.799>
- [5] Fakhry N, Puymeraill L, Michel J, Santini L, Lebreton-Chakour C, Robert D, et al (2013) Analysis of hyoid bone using 3D geometric morphometrics: an anatomical study and discussion of potential clinical implications. *Dysphagia.* 28:435-445. <https://doi.org/10.1007/s00455-013-9457-x>
- [6] Auvenshine RC, Pettit NJ (2020) The hyoid bone: an overview. *CRANIO.* 38(1):6-14. <https://doi.org/10.1080/08869634.2018.1487501>
- [7] Bosma J (1963) Oral and pharyngeal development and function. *J Dent Res.* 2:375-80. <https://doi.org/10.1177/00220345630420014301>
- [8] Kadir D, Osman S, Mehmet Ali M (2015) The morphometric development and clinical importance of the hyoid bone during the fetal period. *Surg Radiol Anat.* 37:43-54. <https://doi.org/10.1007/s00276-014-1319-1>
- [9] Kawakami M, Yamamoto K, Fujimoto M, Ohgi K, Inoue M, Kirita T (2005) Changes in tongue and hyoid positions, and posterior airway space following mandibular setback surgery. *J Craniomaxillofac Surg.* 33(2):107-110. <https://doi.org/10.1016/j.jcms.2004.10.005>
- [10] Green H, James RA, Gilbert JD, Byard RW (2000) Fractures of the hyoid bone and laryngeal cartilages in suicidal hanging. *J Clinl Forensic Med.* 7(3):123-126. <https://doi.org/10.1054/jcfm.2000.0419>
- [11] Balseven-Odabasi A, Yalcinozan E, Keten A, Akçan R, Tumer AR, Onan A, et al (2013) Age and sex estimation by metric measurements and fusion of hyoid bone in a Turkish population. *J Forensic Leg Med.* 20(5):496-501. <https://doi.org/10.1016/j.jflm.2013.03.022>
- [12] Sheng CM, Lin LH, Su Y, Tsai HH (2009) Developmental changes in pharyngeal airway depth and hyoid bone position from childhood to young adulthood. *Angle Orthod.* 79(3):484-490. <https://doi.org/10.2319/062308-328.1>
- [13] Koç N, Parlak Ş (2020) Simple bone cyst of the hyoid: A radiological diagnosis and follow-up. *Dent Med Probl.* 57(3):333-337. <https://doi.org/10.17219/dmp/120079>
- [14] Jadav D, Shedje R, Kanchan T, Meshram V, Garg PK, Krishan K (2022) Age-related changes in the hyoid bone: An autopsy-based radiological analysis. *Med Sci Law.* 62(1):17-23. <https://doi.org/10.1177/00258024211020278>
- [15] Kim DI, Lee UY, Park DK, Kim YS, Han KH, Kim KH, Han SH (2006) Morphometrics of the hyoid bone for human sex determination from digital photographs. *J Forensic Sci.* 51(5):979-984. <https://doi.org/10.1111/j.1556-4029.2006.00223.x>
- [16] Logar CJ, Peckmann TR, Meek S, Walls SG (2016) Determination of sex from the hyoid bone in a contemporary White population. *J Forensic Leg Med.* 39:34-41. <https://doi.org/10.1016/j.jflm.2016.01.004>
- [17] Ichijo Y, Takahashi Y, Tsuchiya M, Marushita Y, Sato T, Sugawara H (2016) Relationship between morphological characteristics of hyoid bone and mandible in Japanese cadavers using three-dimensional computed tomography. *Anat Sci Int.* 91:371-381. <https://doi.org/10.1007/s12565-015-0312-z>
- [18] Kindschuh SC, Dupras TL, Cowgill LW (2010) Determination of sex from the hyoid bone. *Am J Phys Anthropol.* 143(2):279-284. <https://doi.org/10.1002/ajpa.21315>
- [19] Papadopoulos N, Likyaki-Anastopoulou G, Alvanidou E (1989) The shape and size of the human hyoid bone and a proposal for an alternative classification. *J Anat.* 163:249-260.
- [20] Koebke J, Saternus K (1979) Zur morphologie des adulten menschlichen Zungenbeins. *Z Rechtsmed.* 84:7-18. <https://doi.org/10.1007/BF02091980>

- [21] Martinez I, Arsuaga JL, Quam R, Carretero JM, Gracia A, Rodriguez L (2008) Human hyoid bones from the middle Pleistocene site of the Sima de Los Huesos (Sierra de Atapuerca, Spain). *J Hum Evolution*. 54:118-124. <https://doi.org/10.1016/j.jhevol.2007.07.006>
- [22] Leksan I, Marcikic M, Nikolic V, Radic R, Selthofer R (2005) Morphological classification and sexual dimorphism of hyoid bone: New approach. *Coll Anthropol*. 29(1):237-242.
- [23] Mukhopadhyay PP (2010) Morphometric features and sexual dimorphism of adult hyoid bone: A population specific study with forensic implications. *J Forensic Leg Med*. 17(6):321- 324. <https://doi.org/10.1016/j.jflm.2010.04.014>
- [24] Kopuz C, Ortug G (2016) Variable Morphology of the Hyoid Bone in Anatolian Population: Clinical Implications-A Cadaveric Study. *Int J Morphol*. 34(4): 1396-1403. <https://doi.org/10.4067/S0717-95022016000400036>
- [25] Chang HS (1967) Anatomical studies on the hyoid bone of Korean. *Mod Med*. 6(4):427-440.
- [26] Miller KWP, Walker PL, O'Halloran RL (1998) Age and sex related variation in hyoid bone morphology. *J Forensic Sci*. 43(6):1138-1143.
- [27] Harjeet JI (1996) Shape, size and sexual dimorphism of the hyoid bone in Northwest Indians. *J Anat Soc India*. 45(1):4-22.
- [28] Dursun A, Ayazoğlu M, Ayyıldız VA, Kastamoni Y, Öztürk K, Albay S (2021) Morphometry of the hyoid bone: a radiological anatomy study. *Anatomy*. 15(1):44-51. <https://doi.org/10.2399/ana.21.827696>
- [29] Radunovic M, Vukcevic B, Radojevic N (2018) Asymmetry of the greater cornua of the hyoid bone and the superior thyroid cornua: a case report. *Surg Radiol Anat*. 40:959-961. <https://doi.org/10.1007/s00276-018-2041-1>
- [30] Bahşi İ (2019) An anatomic study of the supratrochlear foramen of the humerus and review of the literature. *Eur J Ther*. 25(4):295-303. <https://doi.org/10.5152/EurJTher.2019.18026>

How to Cite;

Nteli Chatzioglou G, Toklu E, Bayraktar E, Ertaş A, Kale A, Coşkun O, Öztürk A, Gayretli Ö (2023) Morphological and Morphometric Variations of the Hyoid Bone in Anatolian Population. *Eur J Ther*. <https://doi.org/10.58600/eurjther1721>