

# Anatomical features of sella turcica with comprehensive literature review

Vildan Önal<sup>1</sup> , Ayşegül Evren<sup>2</sup> , Gki onoul Nteli Chatzioglou<sup>3\*</sup> , Ayfer Metin Tellioglu<sup>3</sup> 

## SUMMARY

**OBJECTIVE:** This study aimed to explore the relationship between skeletal patterns and the frequency of sella turcica bridging in a sample of young Turkish adults in order to provide a better understanding of the relationship between craniofacial morphology and sella turcica abnormalities.

**METHODS:** A total of 90 individuals aged between 18 and 25 years were examined in this study. The individuals were classified according to their skeletal pattern, specifically Class I, Class II, and Class III. Each group consisted of 15 males and 15 females. The length, depth, and anteroposterior diameter of sella turcica were calculated. The shape and bridging of sella turcica were estimated using lateral cephalometric images. All data were correlated and statistically analyzed according to skeletal patterns, genders, and age.

**RESULTS:** The mean length, depth, and anteroposterior diameter of sella turcica were  $7.02 \pm 2.13$ ,  $7.56 \pm 1.38$ , and  $10.54 \pm 1.3$  mm in Classes I–III, respectively. There was no significant difference between the dimensions of sella turcica according to gender and age ( $p > 0.05$ ). The length of sella turcica was larger in Class III, and the depth of sella turcica was larger in Class II individuals ( $p < 0.05$ ). A total of 44.4% of the individuals had normal sella turcica, while the remaining 56.6% had other types of sella turcica. It was determined that 31.1% of the individuals have no calcification, 62.2% had partial calcification, and 6.7% had total calcification.

**CONCLUSION:** The normal dimensions, shape, and bridging of the sella turcica can be used by the orthodontist for diagnosis, treatment planning, and evaluation of various pathological conditions associated with the sella turcica.

**KEYWORDS:** Abnormalities, craniofacial. Morphology. Cranium. Sella turcica.

## INTRODUCTION

The sella turcica is crucial in the radiological assessment of the craniofacial and neurocranial regions. It is situated on the upper surface of the sphenoid bone's body<sup>1-3</sup>. The three parts of this structure, namely, the dorsum sella, tuberculum sella, and fossa hypophysialis, were given the name “sella turcica” because they approximate the shape of a Turkish saddle. The pit in which the pituitary gland sits is called the hypophysial or pituitary fossa, which is found in the middle cranial fossa. The anterior wall of the pituitary fossa is formed by the tuberculum sella, while the posterior wall is formed by the dorsum sella. The processes on both sides of the tuberculum sella are called the middle clinoid process, the superior-lateral corners of the dorsum sella are called the posterior clinoid process, and the posterior processes of the lesser wings (of sphenoid bones) are the anterior clinoid process<sup>1</sup>. As a result, the pituitary gland and the sella turcica are found in a close relationship. Moreover, the development of the pituitary gland is faster than the sella turcica. For this

reason, the development of the pituitary gland is completed before the sella turcica is entirely finished. Any pathology that occurs in the pituitary gland during this development will also affect the morphology of the sella turcica<sup>4,5</sup>. Therefore, knowing the morphology of the sella turcica is essential not only for the evaluation of craniofacial morphology but also for the diagnosis of pituitary gland anomalies and various syndromes<sup>6</sup>.

The sella turcica has clinical relevance in various medical fields, including endocrinology and neurology. In recent years, the evaluation of sella turcica has gained significant attention due to its diagnostic and management implications in a variety of conditions. One of the areas where sella turcica morphology can help is in the diagnosis and management of genetic syndromes such as acromegaly and empty sella syndrome. A recent systematic study has discussed the sella turcica's morphology in patients with genetic syndromes<sup>7</sup>. The study reviewed 15 articles and found that patients with genetic syndromes such as Down syndrome, Marfan syndrome, and Turner syndrome had

<sup>1</sup>Istanbul University, Faculty of Medicine, Department of Anatomy – Istanbul, Turkey.

<sup>2</sup>İnönü University, Faculty of Dentistry, Department of Orthodontics – Malatya, Turkey.

<sup>3</sup>Istanbul Health and Technology University, Faculty of Medicine, Department of Anatomy – Istanbul, Turkey.

\*Corresponding author: gkionoul.chatzooglou@istun.edu.tr

Conflicts of interest: the authors declare there is no conflicts of interest. Funding: none.

Received on May 04, 2023. Accepted on May 20, 2023.

variations in sella turcica morphology compared with individuals without genetic syndromes. These variations included increased or decreased size, altered shape, and increased bridging. The authors suggest that knowledge of these variations could aid in the diagnosis and treatment of genetic syndromes, as well as aid in understanding the underlying genetic mechanisms that influence craniofacial development. Another reported study<sup>8</sup> has analyzed the empty sella syndrome, which is a condition characterized by a partially or completely empty sella turcica. Sella turcica's volumetric assessment can also aid in the diagnosis and management of pituitary tumors, which may cause hormonal imbalances<sup>9</sup>. Furthermore, the evaluation of sella turcica can help in transnasal endoscopic approaches, which are becoming increasingly popular in pituitary surgery<sup>10</sup>. In addition, the morphology of the sella turcica can be evaluated as a part of craniofacial growth monitoring, particularly in children with unilateral cleft lip and palate (UCLP), to assess sella turcica bridging and tooth agenesis. The relationship between sella turcica bridging and tooth agenesis in children with UCLP has been reported in the literature<sup>11</sup>. One hundred and sixteen UCLP patients' dental and radiographic records were analyzed, and a significant correlation was found between sella turcica bridging and tooth agenesis. The findings suggested that sella turcica bridging can be used as a predictor of tooth agenesis in children with UCLP, which can aid in early identification and treatment planning<sup>11</sup>. The evaluation of sella turcica can be performed by X-ray or computed tomography (CT). Both of these are commonly used diagnostic imaging techniques that use ionizing radiation to create images of the body's internal structures. While CT has advantages such as detecting abnormalities and producing detailed 3D images, it also has drawbacks such as higher radiation exposure, longer procedure time, and higher cost compared with X-ray. X-ray, on the contrary, is quick, easy, and cost-effective and is routinely used in today's orthodontic diagnosis and treatment planning.

In this study, we aimed to assess the morphology of sella turcica using lateral cephalometric X-ray images. The study focused on evaluating sella turcica morphology in orthodontic patients but acknowledges the broader clinical implications of this assessment in other medical fields. Hence, we hope to contribute to the growing body of literature on the clinical relevance of sella turcica evaluation and its potential applications in various medical fields.

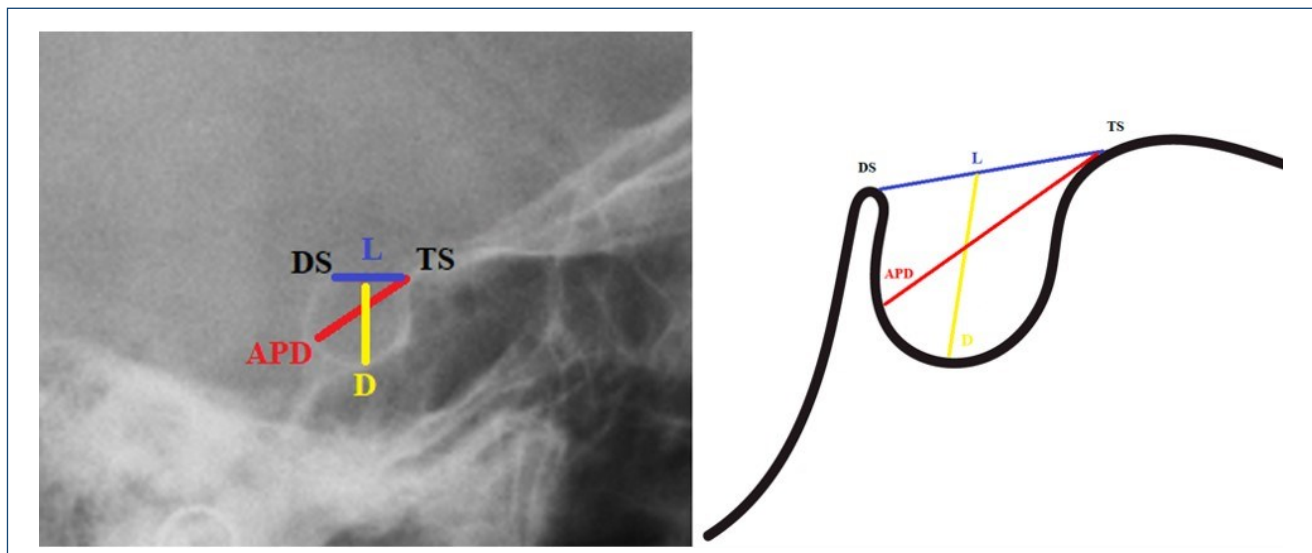
## METHODS

This retrospective study was conducted after obtaining ethical approval from the Inonu Health Sciences Clinical Research Ethics

Committee (date: 05.01.2021; number: 1339). The lateral cephalometric X-ray images recorded as skeletal Class I, Class II, and Class III at Inonu University Faculty of Dentistry, Department of Orthodontics between 01.01.2017 and 01.12.2020 were included. Young adults aged between 18 and 25 years with no history of orthognathic surgery and no head and neck trauma were included in the study. First, the anteroposterior angle between the maxilla and mandible was detected which is an angle known as ANB angle. This angle refers to a cephalometric measurement used in orthodontic diagnosis to determine the relationship between the maxilla and the mandible. It represents the angle formed by the intersection of two lines: the AN line, which connects the A point (the most anterior point of the maxilla) and the Nasion (the point at the junction of the frontal and nasal bones), and the NB line, which connects the Nasion and the B point (the most anterior point of the mandible). This measurement is commonly used to assess skeletal discrepancies and plan orthodontic treatment. In this way, according to the ANB angle, the classification was determined as skeletal Class I, Class II, and Class III. For each group, the images of 90 Turkish individuals registered in the archive were selected randomly, taking into account equal gender distribution (45 male and 45 female). Afterward, the length, the depth, and the anteroposterior diameter of sella turcica were calculated. For the length, the distance between the apex of the tuberculum sella and dorsum sella was considered. The length of the perpendicular line drawn from the length of sella turcica to the deepest point of the floor of the sella turcica was taken into account for the calculation of the depth of sella turcica. Finally, the last morphometric parameter (anteroposterior diameter) was measured between the tuberculum sella and the furthest point on the posterior-inner wall of the pituitary fossa (Figure 1). After morphometric measurements, morphological evaluations of sella turcica were made as follows:

1. *Determination of the shape of sella turcica:* According to the classification of Axelsson et al.<sup>9</sup>, it was classified as normal, double contour of the floor, oblique anterior wall, pyramidal shape of dorsum sella, bridging of sella turcica, and irregular shape of sella turcica.

2. *Determination of bridging of sella turcica:* According to the classification of Leonardi et al.,<sup>10</sup> the bridging of sella turcica was classified into three types based on the morphology and extent of the bony bridge. In Type I, the bridging was characterized by the absence of calcification of the bony bridge. In this type, the bony bridge was composed of fibrous tissue without any evidence of mineralization, also known as incomplete or uncalcified bridging. Type II was characterized by the partial calcification of the bony bridge where the



**Figure 1.** Demonstration of morphometric measurements of sella turcica. The length of sella turcica (blue line): the distance between the apex of the tuberculum sella and dorsum sella; the depth of sella turcica (yellow line): the length of the perpendicular line drawn from the length of sella turcica to the deepest point of the floor of the sella turcica; the anteroposterior diameter of sella turcica (red line): the distance between the tuberculum sella and the furthest point on the posterior-inner wall of the pituitary fossa. TS: tuberculum sella; DS, dorsum sella; L, length of sella turcica; APD, anteroposterior diameter of sella turcica; D, depth of sella turcica.

bony bridge contained both fibrous tissue and calcified tissue. This type is also known as partially calcified bridging. Finally, in Type III, the bridging was characterized by the complete calcification of the bony bridge. The bony bridge was fully composed of calcified tissue, which is known as completely calcified bridging.

The morphological evaluations and morphometric measurements were performed by the same specialist dentist and researcher A.E., who used the Planmeca Romexis 3.5.1.R program. The X-ray images were taken with a Planmeca branded X-ray device with serial number RPP11161, with the person's head fixed to the cephalostat, the Frankfort horizontal plane parallel to the ground, the central beam perpendicular to the patient's mid-oxal plane, and the teeth in the centric occlusion position.

### Statistical analysis

The "independent-sample t-test" and "Mann-Whitney U test" were used to compare two independent groups, while the "one-way ANOVA test" and the "Kruskal-Wallis H test" were used to compare more than two independent groups. Examination of the relationships between the scales was determined by "Spearman's rank differences correlation coefficient." Values less than  $p < 0.05$  were considered statistically significant. The SPSS v26 (IBM Inc., Chicago, IL, USA) statistical package program was used for statistical analysis of the data.

## RESULTS

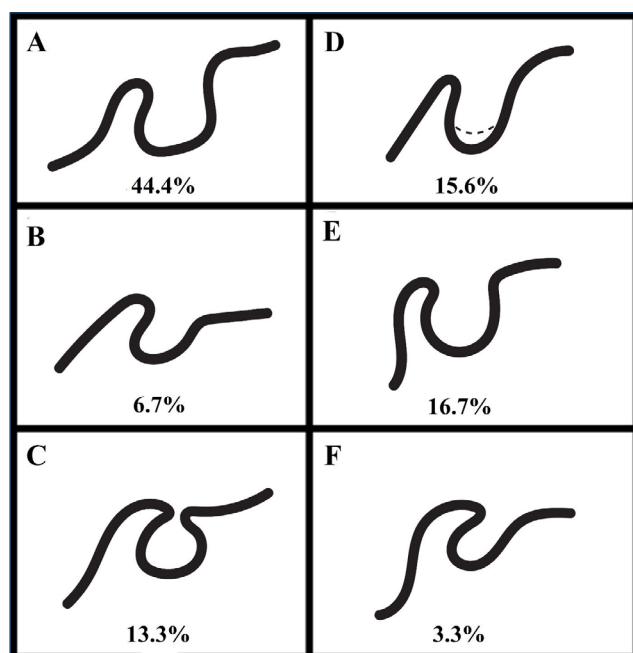
Our study included 45 males and 45 females of skeletal Class I (30), Class II (30), and Class III (30) aged  $20.46 \pm 2.27$  years. The mean length, depth, and anteroposterior diameter of the sella turcica were  $7.02 \pm 2.13$ ,  $7.56 \pm 1.38$ , and  $10.54 \pm 1.31$  mm, respectively. There was no significant difference between the morphometric measurements and the genders or age ( $p > 0.05$ ). However, the mean length, depth, and diameter of Class I were  $6.63 \pm 2.16$ ,  $7.52 \pm 1.35$ , and  $10.25 \pm 1.56$  mm. The mean values of these morphometric results of Class II and Class III were found as  $6.41 \pm 1.56$ ,  $7.91 \pm 1.24$ ,  $10.73 \pm 1.05$  and  $8.02 \pm 2.29$ ,  $7.25 \pm 1.52$ ,  $10.63 \pm 1.27$  mm, respectively. The statistical results have shown a significant difference between the skeletal classification (Class I–Class II–Class III) and the length or depth measurements ( $p < 0.05$ ), while the results of the anteroposterior diameter between the skeletal classification have not shown a significant correlation ( $p > 0.05$ ) (Table 1).

The results of morphological evaluation of sella turcica according to the shape were observed as normal, oblique anterior wall, bridging of sella turcica, double contour of the floor, pyramidal, and irregular dorsum sella in 44.4% (18 in males; 22 in females), 6.7% (5 in males; 1 in females), 13.3% (5 in males; 7 in females), 15.6% (6 in males; 8 in females), 16.7% (8 in males; 7 in females), and 3.3% (3 in males; 0 in females), respectively (Figure 2).

**Table 1.** Comparison and measurement of sizes of sella turcica in different skeletal patterns.

Unit (mm)	Class	n	Median (min–max)	Mean±SD	p-value
Length	Class I	30	6.80 (1.80–10.70)	6.63±2.16	0.017*
	Class II	30	6.45 (2.90–10.50)	6.41±1.56	
	Class III	30	7.45 (3.40–11.90)	8.02±2.29	
Depth	Class I	30	7.80 (3.20–9.20)	7.52±1.35	0.042*
	Class II	30	8.25 (4.80–9.40)	7.91±1.24	
	Class III	30	7.35 (3.20–10.60)	7.25±1.52	
Diameter	Class I	30	10.35 (6.70–14.00)	10.25±1.56	0.322
	Class II	30	10.90 (8.70–12.70)	10.73±1.05	
	Class III	30	10.55 (7.40–13.10)	10.63±1.27	

SD: standard deviation. \*The results were evaluated at 95% reliability,  $p < 0.05$  significance level.



**Figure 2.** The frequency of types of sella turcica. (A) Normal type. (B) Oblique anterior wall. (C) Sella turcica bridging. (D) Double contour of the floor. (E) Pyramidal shape of the dorsum sella. (F) Irregularity on the posterior part of the sella turcica.

Finally, the frequency of bridging of sella turcica according to the Type I (no calcification), Type II (partial calcification), and Type III (total calcification) was recorded. In 31.1% ( $n=28$ ) of 90 participants, the sella turcica had no calcification, while partial ( $n=56$ ) and total ( $n=56$ ) calcifications were recorded equally for the remaining 112 participants. The results showed that, among individuals with Class I skeletal patterns, 35.7% ( $n=10$ ) had Type I bridging of the sella turcica, 32.1% ( $n=18$ ) had Type II bridging, and 33.3% ( $n=2$ ) had Type III bridging. For those with Class II skeletal patterns, 14.3% ( $n=4$ ) had Type I bridging, 42.9% ( $n=24$ ) had Type II bridging, and 33.33%

( $n=2$ ) had Type III bridging. Finally, among those with Class III skeletal patterns, 50% ( $n=14$ ) had Type I bridging, 25% ( $n=14$ ) had Type II bridging, and 33.3% ( $n=2$ ) had Type III bridging.

## DISCUSSION

The sella turcica serves as a stable reference point for measuring the relative positions of other craniofacial structures. This information can then be used to diagnose various dental and skeletal abnormalities and plan orthodontic treatment. The S point, also known as the sella point, is a cephalometric landmark located at the deepest point on the sella turcica. It is used in orthodontics to evaluate the position of the maxilla relative to the cranial base. The distance between the “S point” and the anterior cranial base can be measured, and this measurement can provide valuable information in the diagnosis and treatment of various dentofacial anomalies<sup>1,12-14</sup>.

The results of mean depth and anteroposterior diameter of our study were found similar to the findings reported by Muhammed et al.<sup>15</sup>, while the length mean was reported as higher. The mean of the length, depth, and anteroposterior diameter of our study were observed similar to the findings reported by Shestra et al.<sup>16</sup>, while the results reported by Ghaida et al.<sup>17</sup> and Yasir et al.<sup>18</sup> have shown a few millimeter differences. It is thought that this difference is due to ethnic diversity, environmental factors, sample size, and so on. It was determined that the length, depth, and anteroposterior diameter of sella turcica did not show a statistically significant difference between the genders. Similarly, Shrestha et al.<sup>16</sup> and Akolfide<sup>19</sup> reported that there was no significant correlation according to gender. However, in studies with a wider age range, it has been reported that the length of the sella turcica differs between the genders<sup>6,20,21</sup>. According to the correlation between age and

morphometric results of sella turcica, the findings had no significant correlation in our study, while the results of Acheson and Archer<sup>22</sup> showed significant differences between the genders. In a study by Axelsson et al.<sup>21</sup>, it was concluded that the depth and diameter of the sella turcica raised with puberty, but the change in the length of the sella turcica was insignificantly small. In our study, it was concluded that there was no significant relationship between the size of sella turcica and age. It can be thought that this result is because the individuals included in our study were after puberty.

The relationship between skeletal patterns and dimensions of sella turcica is still unclear in the current literature. Alkofide<sup>18</sup> stated that the diameter of the sella turcica was larger in Class III individuals than in Class II individuals, while Shresta et al.<sup>16</sup> stated that both the diameter and length of the sella turcica were greater in Class III individuals than in Class II individuals. Similarly, Sathyanarayana et al.<sup>6</sup> reported that the diameter of sella turcica had a larger diameter in Class III individuals than in Class II individuals. On the contrary, there is also a study that skeletal patterns and dimension of sella turcica have no significant correlation<sup>23,24</sup>.

While 44.4% of the individuals included in our study had normal type sella turcica, 56.4% had other types of sella turcica. Axelson et al.<sup>21</sup> reported that 68% of the individuals included in their study had normal type sella turcica. Similar frequency (61–67%) has been reported by Sathyanarayana et al.,<sup>6</sup> Alkofide<sup>19</sup>, and Shah et al.,<sup>24</sup> while Magat and Sener<sup>23</sup> reported 39% frequency in the Turkish population. In our study, the normal sella turcica type was the most frequent type found in 44.4%, while the least frequent sella turcica type was the irregular sella turcica (3.3%).

Finally, according to the literature, Type I, Type II, and Type III classifications were found as 56.4, 33.7, and 23.5% by Leonardi et al.<sup>25</sup> and 65, 23.3, and 11.67% by Shrestha et al.<sup>16</sup>, respectively. However, in our study, Type II was found as the highest with 62.2%.

Even so, some authors suggested that the frequency of sella turcica bridging increased in the rate of severe craniofacial anomaly or by receiving surgical treatment Beक्टर et al.<sup>26</sup>.

In addition, the pituitary gland is important because of its proximity to the hypothalamus and its relationship with the optic chiasm, sphenoid sinus, and cavernous sinus<sup>1</sup>. Recent developments in endoscopy have allowed trans-nasal endoscopic

approaches to be performed in and around the sellar region, especially in the posterior clinoid processes. As advanced radiological examinations are required for the three-dimensional evaluation of anatomical structures in the preoperative period, determining the presence of any sella turcica variation on lateral cephalometric radiographs may be useful as preliminary information and this may be a guide in the preoperative period<sup>27</sup>.

## CONCLUSION

There was no statistically significant difference between the morphometric measurements of sella turcica according to age and gender. The length values of the individuals in Class III were statistically higher than the individuals in Class II, and the depth values of the individuals in Class II were statistically higher than the individuals in Class III. The most common type of sella turcica was normal sella turcica, and the most common type of bridging was partial calcification. It is important to reveal the morphology and variations of sella turcica in terms of raising awareness among orthodontists. Similarly, we suppose that it can contribute to the evaluation of surgical procedures for radiologists and surgical clinicians.

## ETHICAL STATEMENT

This study was approved by the Inonu Medical Faculty Local Ethics Committee. (No. 2021/1339).

## ACKNOWLEDGMENTS

We thank Abdullah Celik for his guidance throughout the study and Kaan Güçlü for his assistance in improving the figures.

## AUTHORS' CONTRIBUTIONS

**VÖ:** Conceptualization, Validation, Visualization, Writing – original draft, Writing – review & editing. **AE:** Data curation, Formal Analysis, Investigation, Methodology. **GNC:** Formal Analysis, Visualization, Writing – original draft, Writing – review & editing. **AMT:** Data curation, Formal Analysis, Resources, Software.

## REFERENCES

1. Kjær I. Sella turcica morphology and the pituitary gland—a new contribution to craniofacial diagnostics based on histology and neuroradiology. *Eur J Orthod.* 2015;37(1):28–36. <https://doi.org/10.1093/ejo/cjs091>
2. Drake RL, Vogl AW, Mitchell AWM. *Gray's anatomy for students* E-book. Amsterdam: Elsevier Health Sciences; 2009.
3. Meyer-Marcotty P, Reuther T, Stellzig-Eisenhauer A. Bridging of the sella turcica in skeletal Class III subjects. *Eur J Orthod.* 2010;32(2):148–53. <https://doi.org/10.1093/ejo/cjp081>

4. Kucia A, Jankowski T, Siewniak M, Janiszewska-Olszowska J, Grocholewicz K, Szych Z, et al. Sella turcica anomalies on lateral cephalometric radiographs of polish children. *Dentomaxillofac Radiol*. 2014;43(8):20140165. <https://doi.org/10.1259/dmfr.20140165>
5. Russell BG, Kjær I. Postnatal structure of the sella turcica in down syndrome. *Am J Med Genet*. 1999;87(2):183-8. [https://doi.org/10.1002/\(sici\)1096-8628\(19991119\)87:2<183::aid-ajmg11>3.0.co;2-a](https://doi.org/10.1002/(sici)1096-8628(19991119)87:2<183::aid-ajmg11>3.0.co;2-a)
6. Sathyanarayana HP, Kailasam V, Chitharanjan AB. The size and morphology of sella turcica in different skeletal patterns among South Indian population: a lateral cephalometric study. *J Indian Orthodontic Soc*. 2013;47(4):266-71. <https://doi.org/10.5005/jp-journals-10021-1171>
7. Roomaney IA. Sella turcica morphology in patients with genetic syndromes: a systematic review. *Orthod Craniofac Res*. 2021;24(2):194-205. <https://doi.org/10.1111/ocr.12426>
8. Chiloiro S, Giampietro A, Bianchi A, Marinis L. Empty sella syndrome: multiple endocrine disorders. *Handb Clin Neurol*. 2021;181:29-40. <https://doi.org/10.1016/B978-0-12-820683-6.00003-8>
9. Ortega-Balderas J, Acosta-Flores A, Barrera A, Lugo-Guillen F, Sada-Treviño R, Pinales-Razo M, et al. Volumetric assessment of the sella turcica: a reevaluation. *Folia Morphol*. 2022;81(4):1014-21. <https://doi.org/10.5603/FM.a2021.0112>
10. Chapman P, Singhal R, Gaddamanugu A, Prattipati V. Neuroimaging of the pituitary gland: practical anatomy and pathology. *Radiol Clin*. 2020;58(6):1115-33. <https://doi.org/10.1016/j.rcl.2020.07.009>
11. Antonarakis G, Ghislanzoni S, Fisher D. Sella turcica bridging and tooth agenesis in children with unilateral cleft lip and palate. *Cleft Palate Craniofac J*. 2021;58(11):1382-8. <https://doi.org/10.1177/1055665620984649>
12. Roomaney IA, Chetty M. Sella turcica morphology in patients with genetic syndromes: protocol for a systematic review. *JMIR Res Protoc*. 2020;9(11):e16633. <https://doi.org/10.1177/1055665620984649>
13. Öktem H, Tuncer NI, Sencelikel T, Bağcı Z, Cesaretli S, Arslan A, et al. Sella turcica variations in lateral cephalometric radiographs and their association with malocclusions. *Anatomy*. 2018;12(1):13-9. <https://doi.org/10.2399/ana.18.016>
14. Singh V, Shrestha G. Missed finding of enlarged Sella turcica on lateral cephalogram: a clinical report. *Eur J Clin Orthodontics*. 2014;3(1):20-3. [https://doi.org/10.12889/2014\\_C00035](https://doi.org/10.12889/2014_C00035)
15. Muhammed FK, Abdullah A, Liu Y. A morphometric study of the sella turcica: race, age, and gender effect. *Folia Morphol*. 2020;79(2):318-26. <https://doi.org/10.5603/FM.a2019.0092>
16. Shrestha GK, Pokharel PR, Gyawali R, Bhattarai B, Giri J. The morphology and bridging of the sella turcica in adult orthodontic patients. *BMC Oral Health*. 2018;18(1):45. <https://doi.org/10.1186/s12903-018-0499-1>
17. Ghaida JA, Mistareehi AJ, Mustafa AG, Mistarihi S, Ghozlan HH. The normal dimensions of the sella turcica in jordanians: a study on lateral cephalograms. *Folia Morphol*. 2017;76(1):1-9. <https://doi.org/10.5603/FM.a2016.0038>
18. Yassir A, Nahidh M, Yousif HA. Size and morphology of sella turcica in Iraqi adults. *Mustansiria Dent J*. 2010;7(1):23-30.
19. Alkofide E. Pituitary adenoma: a cephalometric finding. *Am J Orthod Dentofacial Orthop*. 2001;120(5):559-62. <https://doi.org/10.1067/mod.2001.118781>
20. Chidiac J, Shofer F, Al-Kutoubi A, Laster L, Ghafari J. Comparison of CT scanograms and cephalometric radiographs in craniofacial imaging. *Orthod Craniofac Res*. 2002;5(2):104-13. <https://doi.org/10.1034/j.1600-0544.2002.01170.x>
21. Axelsson S, Storhaug K, Kjær I. Post-natal size and morphology of the sella turcica. Longitudinal cephalometric standards for norwegians between 6 and 21 years of age. *Eur J Orthod*. 2004;26(6):597-604. <https://doi.org/10.1093/ejo/26.6.597>
22. Acheson RM, Archer M. Radiological studies of the growth of the pituitary fossa in man. *J Anat*. 1959;93(1):52-67. PMID: 13620617
23. Magat G, Sener SO. Morphometric analysis of the sella turcica in Turkish individuals with different dentofacial skeletal patterns. *Folia Morphol*. 2018;77(3):543-50. <https://doi.org/10.5603/FM.a2018.0022>
24. Shah A, Bashir U, Ilyas T. The shape and size of the sella turcica in skeletal class I, II and III in patients presenting at Islamic international dental hospital, Islamabad. *Pakistan oral Dental J*. 2011;31(1):104-10.
25. Leonardi R, Barbato E, Vichi M, Caltabiano M. A sella turcica bridge in subjects with dental anomalies. *Eur J Orthod*. 2006;28(6):580-5. <https://doi.org/10.1093/ejo/cjl032>
26. Becktor JP, Einersen S, Kjær I. A sella turcica bridge in subjects with severe craniofacial deviations. *Eur J Orthod*. 2000;22(1):69-74. <https://doi.org/10.1093/ejo/22.1.69>
27. Cheng Y, Chen Y, Zhou Z, Zhu J, Feng Y, Zhao G. Anatomical study of posterior clinoid process (PCP) and its clinical meanings. *J Craniofac Surg*. 2015;26(2):537-40. <https://doi.org/10.1097/SCS.0000000000001517>

